

I. Tower's Experience with Arthroprosthetic Cobaltism

I am a practicing orthopedic surgeon with 30 years experience in primary and revision hip, shoulder, and knee arthroplasty. I have a 30-year association with Dartmouth Biomedical Engineering Center, one of the world's foremost nonpartisan, academic, arthroprosthetic explant research facilities, including multiple collaborative peer-reviewed publications.¹⁻⁴ My 40-year medical research experience (onset 1975, CDC)⁵ combined with my Internal Medicine Internship (1983-4, Dartmouth Hitchcock), 4 years of research,⁶ general-medical, and surgical practice (Orthopedic and General) predating my orthopedic residency in the Alaskan Indian Health Service (1984-8), my 4 years of Orthopedic Residency training (OHSU) with peer reviewed publications (1988-92),⁷⁻⁹ and my 27-year private practice career in Anchorage (1992-2019) with a focused interest with the systemic (cobalt poisoning)^{1,10-15} and periarticular failure (histopathologic and mechanical) mechanisms of joint replacement designs and materials^{1-4,7,8,11-16} along with multiple peer-reviewed publications focused on cobalt-chrome metallosis complications,^{1-4,7,8,11-18} and additional publications and presentations touching on the topic of societal-harm related to the American-Medical-Industrial-Complex wherein market forces can drive research and medical education, medical practice, and government regulation rather than science,^{12,17,19} would seem to qualify me as an "expert" on the topic of the metallosis complications of prosthetic joints yet I was denied membership on the FDA Expert Panels addressing these complications in 2010 and 2019.

My personal (as patient), professional (as surgeon), and scientific (as researcher), qualifications directly bearing on arthroprosthetic cobalt-chrome metallosis and my education and experiential foundation that allowed for publication primacy (2010),^{3,10,16} in the discovery that systematic cobalt poisoning (cobaltism) is a complication of primary (first-time) hip replacement, modern (since the archaic Mckee-Farrah metal-on-metal hip of the 1970s)²⁰ hip replacements utilizing cobalt-chrome as an arthroprosthetic material with multiple peer-reviewed publications over the past decade based on focused study of my patients and the peer-reviewed publications of other investigators.^{1,2,11-13,15,17-19}

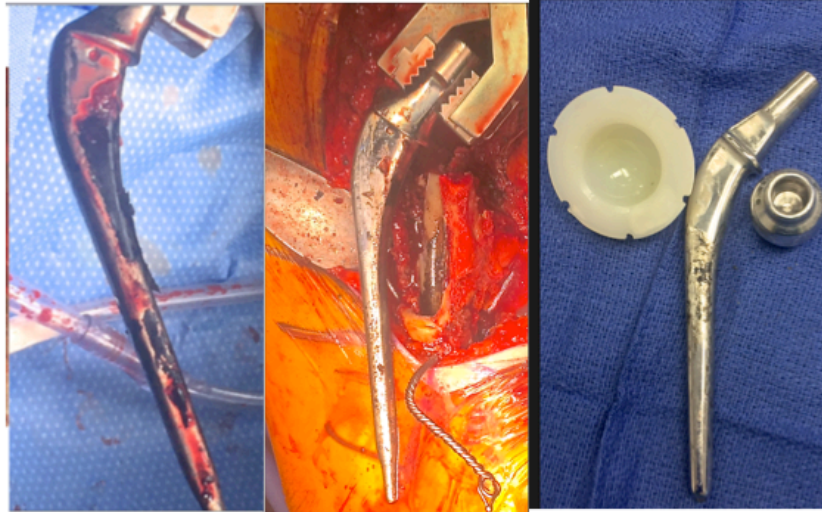
2. Cobalt-Chrome is inherently unsafe for arthroprosthetics compared to proven alternatives

23
24 Modern hip, shoulder, and knee joint replacements employ metal, ceramic, or plastic materials to replace one or both articular surfaces. Iron
25 (FeCrNi), Cobalt (CoCr), and Titanium (TiAlV) are the base metals of arthroprosthetic alloys. Of the three base metals (Cobalt, Iron, Titanium), only
26 cobalt is notably toxic in the laboratory and in humans to the cells of periprosthetic tissues (hip capsule, ligaments, synovium, tendons, muscle, and
27 bone)²⁰⁻²² and multiple organ cell types (white blood cells,²³⁻²⁶ myocardial,^{23,27-38} neurons,^{23,39,40} thyroid²³). Cobalt has been know to result in systemic
28 metal poisoning (encephalopathy, cranial and peripheral neuropathy, cardiomyopathy, and thyroid failure) since the 1950s and is carcinogenic.^{13,20,41-47}

29 Cobalt is in vitamin B-12; humans absorb B-12 produced by bacteria in the gastrointestinal tract because we lack the ability to make it.^{23,43}
30 Element cobalt is not essential to human-life.^{41,43} Cobalt-deficiency occurs in beef-cows⁴⁸ not in humans.^{41,43} Industry funded retrospective anti-science
31 argues that the historical use of oral cobalt-chloride as a hematemic proves that its use in arthroprosthetic devices is safe. In the 1950s cobalt-chloride
32 was thought to be salubrious for anemic patients and was widely used to treat anemic children and adults with anemia related to kidney failure.^{41,49-59} By
33 the end of that decade it was known that such treatment was of little benefit to anemic, kidney failure patients because of its toxicity to the brain, nerves,
34 heart, and thyroid gland, by the 1970s the practice of treating anemia with cobalt-chloride was abandoned due to this toxicity.^{23,60-64} Exposure of workers
35 to cobalt ores and powders resulted in same syndrome sometimes resulting in death or heart transplantation.^{23,41-43,65-73} Low-grade, long-term, industrial,
36 or arthroprosthetic cobalt exposure is linked to cognitive decline,^{23,74} thyroid dysfunction,^{41,43,75,76} cardiomyopathy,^{41,77} and cancer.^{41,45,47,65,78-81}

37 CoCr is a stronger alloy than FeCrNi and that was a rationale for its popularity as an arthroprosthetic material but the strength of a femoral
38 stem is more determined by its dimensions than its composition. The rare fatigue failures of Charnley's historically peerless FeCrNi stem⁸² were solved
39 by upsizing its shape rather than switching to the potentially toxic CoCr alternative.⁸³

40 Industry argues that Cobalt-Chrome (CoCr) is a superior prosthetic material to stainless steel (FeCrNi) for use in cemented polished stems
41 such as Zimmer's Heritage and CPT stems: they appear to confuse popularity with efficacy and their assertion is not supported by a 50-year experience
42 with cemented femoral stems. The "state-of-the-art" material for any cemented polished femoral stem is indisputably FeCrNi based on its superior
43 survivorship (comparative to cemented CoCr stems and uncemented TiAlV stems) in tens of millions of patients that have benefited from the mat-
44 finished FeCrNi Charnley femoral stem or the polish-finished finished FeCrNi Exeter stem.⁸²⁻⁹³ This is not just my opinion: new hip designs and materials
45 are generally benchmarked against the FeCrNi Charnley Low-Friction-Arthroplasty,⁹² because of its common use, long history (50-years), and its seldom
46 surpassed safety and survivorship, particularly for geriatrics.^{82,93} In the Mayo series of 2000 patients with FeCrNi Charnley arthroplasties now followed >
47 40 years the annual risk of failure (revision) for geriatric patient to a material or design problem is < 0.5% per annum.⁹³ The failure of my own Zimmer
48 Heritage polished CoCr stems as early as 8-years (based on elevation of blood and urine cobalt levels) or at 12-years (based on time to revision) due to
49 gross corrosion at the stem-cement interface is both concerning and exceptional.



Patient A (polished Zimmer Heritage CoCr stem) revised 8/18 urine cobalt 10.6, composite FDG PET score -54, 5 hypometabolic cluster areas at 11 years post first cobalt exposure.

Patient B (polished Zimmer Heritage CoCr stem) revised 9/18 urine cobalt 55.4, composite FDG PET score -78, 9 hypometabolic cluster areas at 17 years post first cobalt exposure.

Patient C (polished Zimmer Heritage CoCr stem) revised 12/18 urine cobalt 14.4, composite FDG PET score -172, 20 hypometabolic cluster areas at 20 years post first cobalt exposure.

51

52

53

54

55

56

57

58

59

60

61

62

63

64

65

66

67

68

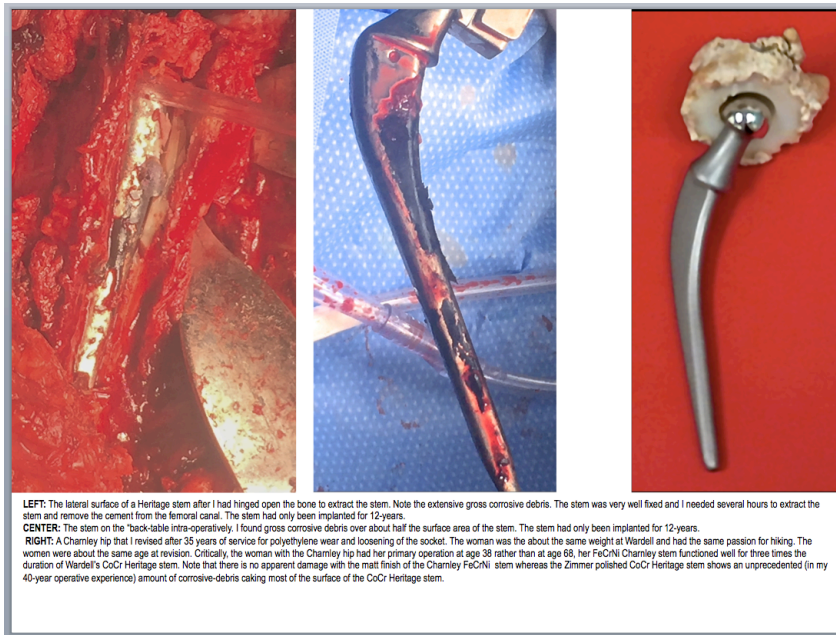
69

70

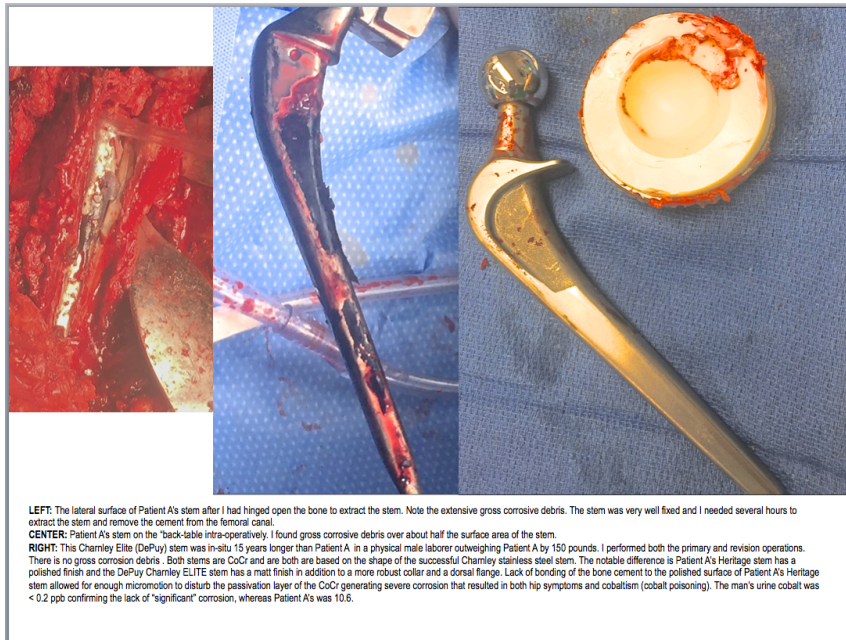
Industry "experts" argue that corrosion is inevitable at the interface between a metallic femoral stem regardless of alloy and that corrosion when it does occur is only "clinically significant" in "rare" cases. Both assertions are unsupported by the medical literature and are counter to my extensive hip revision experience. Millions of Charnley's cemented FeCrNi stems have been implanted. Early in the evolution of Charnley's stem design fatigue fracture of the early "flat-back" variant stem with coincident corrosion of the 316L or EN58J stainless steel alloys were occasionally described.⁹⁴ This infrequent complication was remedied by beefing-up the stem, making it stiffer and stronger, and thereby less prone to fatigue failure.⁹⁵ Even in the rare instances in which corrosion was found during revision of a fractured Charnley stem the amount of corrosive debris was minor compared to what I uncovered when I revised Patients A-C's well fixed CoCr Zimmer Heritage polished stems.⁹⁴

The Charnley Elite stem (DePuy, Warsaw IN) like the Heritage uses CoCr alloy rather than FeCrNi but has a matt finish, a more robust collar, and a dorsal flange, these features limit micro-motion at the stem-cement interface. I cannot find literature report of corrosion occurring with the Charnley Elite implant (matt finished CoCr) and it is reported to have a 1% failure-rate at 12 years in young high-activity patients that are known to be prone to premature implant failure compared to the 4.0% for the Heritage (polished CoCr) at 7-years in a low-demand, elderly, population.⁹⁶ The DePuy Charnley Elite CoCr stem (matt finished, robust collar, proximal dorsal flanges) is a "shape-closed" design that limits the micro-motion at the stem-cement interface, the Zimmer Heritage stem (CoCr alloy, polished finish, minimal collar, no dorsal flanges) is a "force-closed" design which allows for stem-cement micro-motion.⁹⁷⁻⁹⁹ Micro-motion is sine qua non of Mechanically-Assisted-Crevise-Corrosion (MACC), the phenomena that I observed in spades at the time of multiple revisions of Zimmer Heritage stems revised for periprosthetic and systemic cobalt toxicity. Femoral stems with an effective "shape-closed" design (matt-finish, robust collar, dorsal flanges) rarely exhibit "significant" corrosion at the stem-cement interface,^{85,96,97} "force-closed" femoral designs such as Zimmer's CoCr Heritage and CPT, DePuy CoCr Ultima stem, Stryker's FeCrNi Exeter stem, and several abandoned TiAlV femoral stems predictably corrode in patients and on the bench.¹⁰⁰⁻¹⁰⁶

Dr. Tower's Briefing to Dr. Raj Rao, Chairperson FDA Medical Devices Advisory Committee
Expansion of Dr. Tower's 8.5 minutes of Open Public Testimony, November 13 2019



71



72

73

74

75

76

77

78

79

The Exeter femoral stem (Stryker, Kalamazoo MI) is made of FeCrNi and has a polished finish and is shaped to encourage micro-motion between the stem and the cement mantle. This has been reported to result in corrosion and the stem-cement interface but generally of a lesser magnitude that I witnessed in my patients A-C with polished CoCr Zimmer Heritage stems.¹⁰¹ The Exeter hip outperforms even the Charnley hip in National Joint Registry 15-year survivorship data indicating that although corrosion can occur at the stem-cement interface of a polished FeCrNi stem it is of limited periprosthetic or systemic consequence because the byproducts of FeCrNi corrosion are fundamentally less toxic than those liberated by corrosion of a CoCr implant.^{22,107-116}

80

81

82

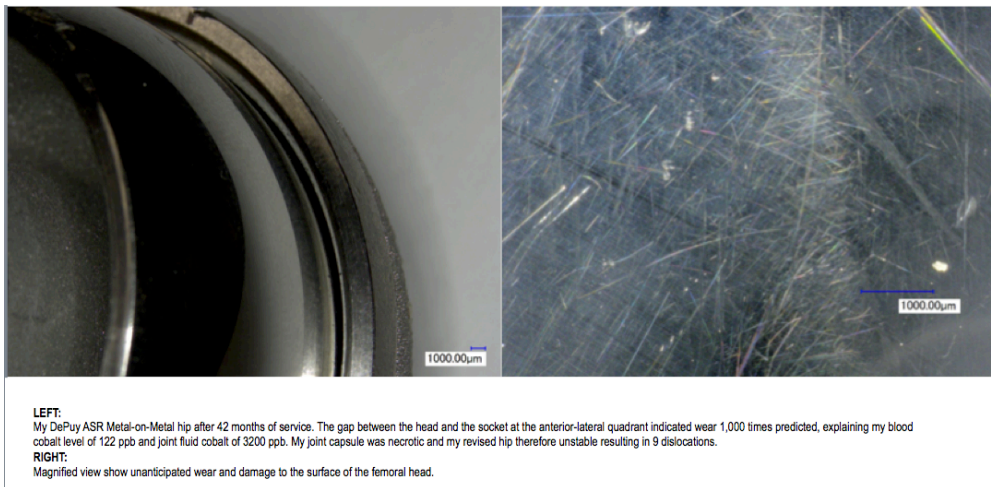
CoCr should never be used for a force-closed (polished) femoral stem because cobalt, in excess, is fundamentally toxic to the periprosthetic tissues and to distant human organs (central and peripheral nervous system, heart, and thyroid).^{20,41,43} It was know at the time of the design and promotion of the Heritage CoCr stem^{98,117} that polished (force-closed) femoral stems, regardless of alloy, were at risk for corrosion at the stem-cement interface.¹⁰⁶ It was also

Dr. Tower's Briefing to Dr. Raj Rao, Chairperson FDA Medical Devices Advisory Committee
Expansion of Dr. Tower's 8.5 minutes of Open Public Testimony, November 13 2019

83 know then that cobalt is fundamentally toxic to the periprosthetic tissues^{20,22,23} and systemically toxic to the human brain, nerves, heart, and thyroid
84 gland.^{20,41} Although corrosion has been reported with the smooth finished classic Charnley FeCrNi "flat-back" stem⁹⁴ and polished FeCrNi dual taper Exeter
85 stem¹¹⁸ it is rarely periprosthetically or systemically toxic because the major constituent the Stainless Steel (FeCrNi) alloy is iron which biologically benign
86 compared to cobalt with is the primary element in the CoCr alloy used for Zimmer's polished CoCr Heritage stem.

87 The harm to patients with polished CoCr cemented "force closed" stems such as Zimmer's CPT and Heritage models and J&J's Ultima stems (gross corrosion
88 at the interface of the polished CoCr stem surface and the poly-methyl-methacrylate (PMMA)) is magnified by most all currently marketed bone cements which contain 10%
89 (by weight) barium sulfate¹¹⁹ which is an abrasive and magnifies the documented corrosion than occurred at the cement-stem interface of polished "force-closed" stems.

90 Industry's assertion that CoCr metallosis produced by arthroprosthetic implants, when it does occur, only "rarely" produces periprosthetic *Adverse Reaction to*
91 *Metallic Debris* (ARMD) is countermanded by both the literature,^{100,103,107,109,120-143} and by my experience as patient,^{3,10,11,16} arthroprosthetic revision surgeon and published
92 authority on the periprosthetic and systemic toxicity of CoCr metallosis,^{2,13-15,144} and as an advocate for reform of the American Medical-Industrial-Complex.^{12,17,19} The
93 proclivity of DePuy's metal-on-metal ASR implant to produce CoCr metallosis and ARMD by wear of its articulation resulted it its formal recall of the marketplace including a
94 systematic monitoring program including blood cobalt determinations and cross-sectional imaging of the hip.^{133,142,145-166}



95 The Styker (Kalamazoo, USA) ABG and Rejuvenate hips and ESKA (Lubeck, Germany) hip have a modular CoCr neck prone to corrosion producing CoCr
96 metallosis at both ends resulting in formal recall from the market of the Styker products with a systematic monitoring program of blood cobalt and cross-sectional imaging at
97 the hip for clinical and sub-clinical pseudotumors.^{107,108,167-184}

Cobaltism Awareness: Systematic Monitoring of Patients at Risk for Taper Corrosion Indicated

510K MoP Hip RECALLED

Rejuvenate Implanted 8/2010
70 YO GENERALLY WELL WOMAN
20 months later:
progressive fatigue, poor sleep, nausea,
weight loss from 140 to 120 pounds,
deafness, myalgia, cognitive decline,
arrhythmia and diastolic dysfunction
B[Co] = 11 PPB

Recalled 7/2012 (at 23 months)
Explanted after 33 months

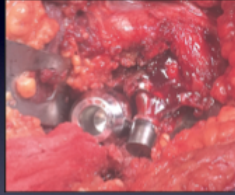
Dr. Tower's Briefing to Dr. Raj Rao, Chairperson FDA Medical Devices Advisory Committee
Expansion of Dr. Tower's 8.5 minutes of Open Public Testimony, November 13 2019

101

Zimmer's VerSys 12/14 taper modular CoCr femoral heads and Stryker's V40 taper CoCr heads are proven to be problematic regardless of whether they are

102


mated to a CoCr stem trunnion or a TiAlV stem trunnion.^{109-115,180}



510K MoP Hip Not recalled

46 y/o Executive at 1* THA, 2009 Zimmer Kinnectiv MoP Hip, Severe Immune GI Syndrome, Oat Allergy, Mast Cell Activation Syndrome, Later Onset of hip pain, Fatigue, Cognitive Decline, **B[Co] = 2.4 ppb, U[Co]=8.0**, Monoclonal IGA, FDG PET (-97, 9 clusters), MS MRI Hip pseudotumor, Hips Revised to Ceramic-on-Plastic, 3 months post revision **B[Co] = 8.7, U[Co]=1.5**, Improved Cognitive Function, Bone Marrow Pending

103



510K MoP Hip Not Recalled

Stryker Accolade "fitted" 2006 for a 68 year-old Professor
8 years later onset of progressive cognitive decline, tremor, fatigue, incoordination, and **B[Co] = 5.8 PPB**
U[Co] = 35 PPB
Joint Fluid [Co] = 1100 PPB
Neurocognitive testing unfit to drive due to incoordination, reaction time, and judgment issues. Revised 8/2016 patient now 78 YO.

"Silent Recall" V40 Taper CrCo heads 10/2016

104

105

Professional awareness that CoCr metallosis is a significant problem that can result in ARMD and systemic toxicity and therefore mandates orthopedic surgeon

106

awareness, monitoring, and if indicated revision surgery is demonstrated by the following tables from the joint recommendations of the *American Academy of Orthopedic*

107

Surgeons (AAOS), the American Hip and Knee Surgeon Society (AHKSS), and the Hip Society that was published January 2014.¹⁸⁵ The consensus opinion was specific to

108

cobalt exposure from Metal-on-Metal hips: but, we have learned from the taper corrosion of Metal-on-Plastic and even Ceramic-on-Plastic hips that both ARMD and

109

cobaltism occur at much lower blood cobalt levels if the systemically circulated cobalt is produced by corrosion as opposed to the wear mechanism seen in Metal-on-Metal

110

hip replacement and hip resurfacing.^{110,113,115,169,185} A blood cobalt of ≥ 3 ppb places a patient with a Metal-on-Metal hip in the moderate-risk category for a complication of

111

CoCr metallosis¹⁸⁵ whereas the threshold blood cobalt for concern is ≥ 1 ppb for patients with a metal-on-plastic or ceramic-on-plastic hip with a taper joining one or more

112

CoCr components.¹⁶⁹ The reason that arthroprosthetically-produced, systemically-circulated cobalt produced by corrosion is more toxic periprosthetically and systemically

113

that that produced by wear of the articular surfaces of a metal-on-metal hip resurfacing relates to the much smaller particle size and more reactive nature of CoCr corrosion

114

byproducts as opposed to much larger CoCr wear particles.^{21,22,43,46,186-189} Critical literature regarding thresholds of blood cobalt for concern for metal-on-metal hips or hips

115

with metal-on-plastic or ceramic-on-plastic articulations prone to corrosion of modular CoCr parts are both by Kwon.^{185,190} At blood cobalt level of 3 ppb is considered to

116

place a patient with a metal-on-metal hip at-risk for ARMD, a lower blood cobalt threshold of 1 ppb is considered concerning with metal-on-plastic or ceramic-on-plastic hip

117

with modular CoCr component.^{185,191} As noted above this reflects the fundamental increased toxicity of CoCr metallosis produced by corrosion at CoCr modular junctions

118

compared to that created by wear of CoCr articular surfaces.^{21,43,46,47,186-189}

119

Dr. Tower's Briefing to Dr. Raj Rao, Chairperson FDA Medical Devices Advisory Committee
Expansion of Dr. Tower's 8.5 minutes of Open Public Testimony, November 13 2019

120
121
122

Risk Stratification for monitoring and revision of patients with Metal-on-Metal hips at-risk for ARMD and Cobaltism (Kwon, JBJS, 2014)

"Low" Risk Group Stratification		"High" Risk Group Stratification	
Patient factors	Patient with low activity level	Patient factors	Female with dysplasia (for hip resurfacing) Patient with high activity level
Symptoms	Asymptomatic (including no systemic or mechanical symptoms)	Symptoms	Symptomatic Severe local hip and/or mechanical symptoms Systemic symptoms
Clinical examination	No change in gait (i.e., no limp, no abductor weakness)	Clinical examination	Change in gait (i.e., limp) Abductor weakness
Implant type	No swelling	Implant type	Swelling Large-diameter femoral head (≥ 36 mm) modular or nonmodular MoM THA Recalled MoM implant
Radiographs (2 views \pm serial for comparison when available)	Small-diameter femoral head (< 36 mm) modular MoM THA hip resurfacing in males < 50 with osteoarthritis Optimal acetabular cup orientation ($40^\circ \pm 10^\circ$ inclination for hip resurfacing)	Radiographs (2 views \pm serial for comparison when available)	Suboptimal acetabular cup orientation Implant osteolysis/loosening Within normal limits
Infection work-up (ESR, CRP, \pm hip aspiration)	No implant osteolysis/loosening	Infection work-up (ESR, CRP, \pm hip aspiration)	High (> 10 ppb)
Metal ion level test (if available)	Within normal limits	Metal ion level test	Presence of abnormal tissue reactions with involvement of surrounding muscles and/or bone Solid lesions
Cross-sectional imaging (if available); these studies include MARS MRI; ultrasound or CT when MRI contraindicated or MARS protocol not available	Low (< 3 ppb)	Cross-sectional imaging (MARS MRI; ultrasound or CT when MRI contraindicated or MARS protocol not available)	Cystic lesions with thickened wall Mixed solid and cystic lesions
Treatment recommendation	Within normal limits	Treatment recommendation	Consider revision surgery
	Annual follow-up		

Sensitivity and Specificity of Metal Ion Level in Predicting Adverse Local Tissue Reactions Due to Head-Neck Taper Corrosion in Primary Metal-on-Polyethylene Total Hip Arthroplasty

Young-Min Kwon, MD, PhD¹, John MacAuliffe, MEng, Paul G. Arauz, PhD,
Yun Peng, PhD

Department of Orthopaedic Surgery, Massachusetts General Hospital, Harvard Medical School, Boston, Massachusetts

123

124

Conclusions: Although metal ion levels alone should not be relied on as the sole parameter to determine revision surgery, serum cobalt level of > 1 ng/mL (1 ppb) and Co/Cr ratio > 2 thresholds provide evidence based practical information for surgeons when interpreting metal ion levels in MoP THA patients for clinically relevant head-neck taper corrosion.¹⁹¹

125

126

127

128

129

Between 2010 and 2015 Dr. Thomas Mego (chair Providence Alaska Medical Center Department of Pathology) and I reviewed the histopathology of 48-failed Metal-on-Metal and Metal-on-Plastic hips that were revised because of periprosthetic and systemic complications of CoCr metallosis. Histopathologic findings typically show metallosis in the form of inclusions in macrophages and in a "slate-blue" staining of the cytoplasm. Variable degrees of synovial-necrosis were the most common finding. We only found ALVAL lesions (focal lymphoid infiltrates around small blood vessels) in a minority of patients, generally those patients with a hyper-acute presentation (severe symptoms at the hip within months of hip implantation). The literature on the histopathology of ARMD supports Dr. Mego's and my experience, the histologic picture of ARMD is highly variable; metallosis and necrosis are generally the most consistent microscopic findings. Prominent ALVAL lesions appear in a minority of cases, generally those patients that respond in an allergic fashion chrome-cobalt metallosis.^{20,148,192-195}

130

131

132

133

134

135

COBALT TOXICITY AFTER McKEE HIP ARTHROPLASTY

D. ANTHONY JONES, H. KEITH LUCAS, MICHAEL O'DRISCOLL, C. H. G. PRICE and
B. WIBBERLEY, BRISTOL, ENGLAND

136

Results of histological examination

Tissues removed from the hip joints of Cases 1, 2, 3, 4 and 6 were studied. The only constant feature of note was widespread necrosis of bone, joint capsule and adjacent muscle, usually but not invariably without any diffuse or focal inflammatory reaction (Figs. 22 to 25),

and accompanied by a great deal of granular fibrinoid or collagen debris.

These changes are by no means specific, and appreciation of their extent, which when wide may suggest a cytotoxic effect, must depend upon the range of tissues sampled by the operating surgeon and the zeal of the examining pathologist. Minor unremarkable inflammatory changes were noted and in two cases scattered tiny round or oval birefringent particles of an unknown nature

137

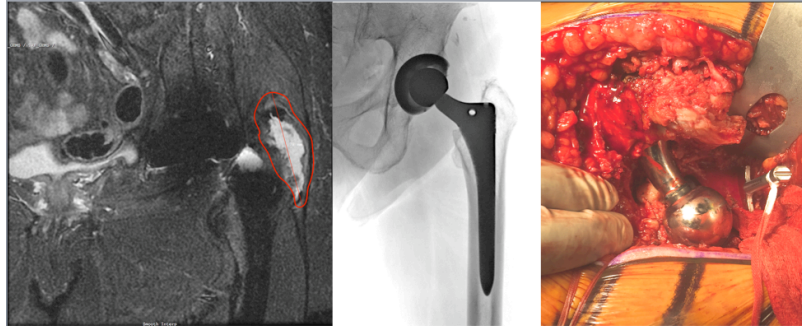
138

139

140

Dr. Tower's Briefing to Dr. Raj Rao, Chairperson FDA Medical Devices Advisory Committee
Expansion of Dr. Tower's 8.5 minutes of Open Public Testimony, November 13 2019

141 My clinical series indicated and "at-risk" hips extend beyond those with a modular cobalt-chrome neck stem^{108,171-174,176,178,179,183,184,196,197} or a hip with a metal-on-
142 metal articulation.^{3,20,25,26,124,138,139,165,166,193,194,198-216} My first appreciation of this was February of 2013 when I revised a series of patients with severe corrosion the Zimmer's
143 12/14 taper junctions when a CoCr VerSys head or Durom CoCr head was used. I was finding this problem throughout Zimmer's product line including Zimmer's popular
144 ML Taper, Kinnectiv, or ZMR TiAlV stems when mated to a VerSys CoCr head articulating with a Longevity Plastic Liner or a Durom CoCr acetabular component. Multiple
145 surgeons including my mentor Dr. Paul Duwelius were reporting this problem of corrosion with Zimmer's 12/14 tapers when a VerSys CoCr or Durom CoCr heads were
146 used.^{109-111,113-115,217} **The case illustrated below is typical of the approximate 30 cases of Zimmer's hips that I have revised due to ARMD since that index case**
147 **early 2013, all revisions were for symptomatic ARMD, with severe periprosthetic tissue damage, and all were because of defective design of stems or tapers**
148 **combined with a poor choice of alloy.** The reason that patients with elevated cobalt levels are closely followed with cross-sectional imaging is that the damage from the
149 metallosis to the periprosthetic tissues can be severe with minimal clinical symptoms resulting in an unsalvageable problem.^{191,218}



LEFT: MRI of left hip of sedentary 71 year-old 132 woman with lateral hip pain and weakness 9 years post hip replacement with Zimmer TiAlV stem and 32 mm CoCr VerSys head with 12/14 taper. Her surgeon in New Jersey was treating her with cortisone injections and he did not check a cobalt level. She moved to Alaska and presented to my clinic with a severe limp because of left hip weakness. The image show a cobalt related pseudotumor with rupture of the hip abductor tendons. Her blood cobalt was 11.
CENTER: Her radiographs show well-positioned, stable, osteointegrated implants, no plastic wear, and no osteolysis.
RIGHT: Intra-operative revision photo, I have partially disengaged the taper to show the gross corrosive debris. The trochanter is "bald" because of rupture of the hip abductor tendons. The appearance of the periprosthetic tissues is similar to Wardell. Fortunately for Wardell we revised her hip before her hip abductor tendons ruptured.

150 My index patient (revised February 2013) for the realization that Zimmer's 12/14 tapers were extremely problematic when mated to a CoCr head is illustrated
151 below. The loss of material from the bore of the CoCr taper adaptor for the Durom head was so severe that I could toggle the modular TiAlV Kinnectiv modular neck back
152 and forth.
153



Final Diagnosis
RIGHT HIP JOINT REVISION ISSUE:
-- DISEASE PROCESS: Detritic synovitis.
-- ACUTE INFLAMMATION: Focal, maximum four neutrophils per hpf.
-- CHRONIC INFLAMMATION: Present, mild-moderate, lymphohistiocytic.
-- ALVAL (Aseptic Lymphocytic Vasculitis-Associated Lesion): Not identified.
-- MONONUCLEAR HISTIOCYTES: Present, patchy, mild-moderate.
-- METAL PARTICLES: Present, mild.
-- MULTINUCLEATED GIANT CELLS: Present, focal.
-- FOREIGN MATERIAL: Present, focal.
-- NECROSIS: Present, fibrinoid, focally calcified.
-- BONE CHIPS: Not identified.

LEFT TOP: Explanted Zimmer Durom CoCr head and CoCr Head socket and modular Zimmer Kinnectiv TiAlV femoral neck.
CENTER TOP: The bore of the CoCr Durom 12/14 taper shows severe damage with loss of material and corrosive debris that resulted in symptomatic ARMD and brain atrophy by MRI with symptoms of imbalance, peripheral neuropathy and cognitive decline. The patient was male, moderately physically active, and was 65 and 170 pounds at time of revision surgery. The hip failed because of CoCr metallosis with ARMD and cobaltism after only ten years of service.
RIGHT BOTTOM: This patient's histopathologic, ALVAL is not a common histopathologic finding in clinically significant CoCr related ARMD. It is present in my experience in only a minority of cases and my experience is mirrored in the literature.

154
155

Dr. Tower's Briefing to Dr. Raj Rao, Chairperson FDA Medical Devices Advisory Committee
Expansion of Dr. Tower's 8.5 minutes of Open Public Testimony, November 13 2019

156 My appreciation that arthroprosthesis generated cobalt is neurotoxic has passed peer review muster many times,^{3,11-13,15-18,144} and even passed conflict-of-
157 interest problematic peer review (most orthopedic surgeons that do peer-review for hip prosthetic related topics for presentation at the annual AAOS meeting are industry
158 consultants¹⁷ allowing for our work using the Cobalt-Symptom-Inventory screen at-risk patients for arthroprosthetic cobaltism and FDG-PET-CT-Brain-Imaging to confirm
159 the diagnosis to be presented at the annual meeting of the AAOS in 2018 (appendix A).

160 Cobalt encephalopathy is not my invention; I was just the first to recognize it as a complication of modern metal-on-metal hip arthroplasty because I
161 experienced it as a patient.^{3,10,11,16,219} Cobalt encephalopathy manifesting as cognitive decline was first described by Jordan in 1997 from chronic cobalt industrial
162 exposure.⁷⁴ Since the 1960s we have known that iatrogenic deafness, blindness, thyroid abnormalities, and heart failure results when cobalt chloride is taken by mouth, as
163 it was to treat anemia, a practice abandoned by 1980 because of its adverse risk to benefit ratio.^{41,42,60-64,220,221} Acute industrial cobalt exposure results in death, heart failure,
164 deafness, blindness, and thyroid abnormalities.^{41,73,222} The fatigue and disabling mood disorder I experienced when my blood cobalt was 80X that considered safe in
165 industry has now been described to be a common early feature of those suffering from arthroprosthetic cobaltism.^{128,132,133,146}

166 3. Industry's Misinformation Campaign is confounding remediation of Arthroprosthetic Cobaltism

167 Industry financed retrospective anti-science argues that a blood cobalt level of 6 ppb (6X that thought safe in industry)²²³ from arthroprosthetic cobalt-chromium
168 metallosis cannot result in systemic toxicity is based on a house of cards of misinformation, the foundation of which is Cardno ChemRisk LLC's (San Francisco, CA) 2013
169 study of blood cobalt levels in 10 generally young, well, men and woman were dosed by mouth with the cobalt-laced dietary supplement (Mineralife, Colorado Springs, CO)
170 for study period of 15, 30, and 90 days with monitoring of blood cobalt, blood counts, hearing, sight, cardiac and thyroid function.²²⁴⁻²³⁴ Cardno ChemRisk LLC fused this
171 study with their theoretical model to calculate blood cobalt levels of 11 dialysis patients treated 8 weeks with oral cobalt-chloride for anemia in one study (Bowie, 1975),²³⁵
172 and 6 patients treated for 90 days (Duckham, 1976)⁶². Then Cardno ChemRisk treated 10 subjects with an oral cobalt laced dietary supplement for 90-days, at 90-days the
173 5 men had an average blood cobalt level of 20 ppb and the 5 women had a mean blood cobalt level of 53 ppd.²²⁸ With impenetrable logic Cardno ChemRisk states that
174 blood cobalt of < 300 ppb should not cause toxicity in patients exposed to arthroprosthetically generated CoCr metallosis.²²⁸

175 Neither Cardno ChemRisk's 10 subjects²²⁸ nor the 17 dialysis patients treated a half century ago^{62,235} contribute any meaningful information concerning
176 poisoning by CoCr periprosthetic metallosis. The 17 renal failure patients absorbed the cobalt from the gastro-intestinal tract, from there it is directly routed to the liver, the
177 human body's first line of defense against toxics and most all that is absorbed is excreted rapidly in the bile and urine, having little opportunity to enter the cells of the heart,
178 brain, nerves, and thyroid gland which is where cobalt's metabolic toxicity is expressed.^{41,43} Furthermore with 17 renal failure patients were dialyzed 3 times a week
179 reducing their serum cobalt concentrations to nil.^{62,235} The CoCr metallosis produced by corrosion or wear of an orthopedic implant is nanoparticulate, bypasses the liver,
180 and is directly presented the brain, nerves, heart, and thyroid gland in a form that more readily transverses the cell membrane than ionic cobalt absorbed through the
181 gastrointestinal tract.^{21,43,46,47,186,188,189} Only 16 of the 27 dialysis patients reported to have tolerated large doses of oral cobalt completed a full 90-days of treatment, Cardno
182 ChemRisk ignores that 3 of the 11 patients reported by Bowie developed deafness and one died shortly after the trial from heart failure.^{228,235,236} The duration of exposure to
183 arthroprosthetically generated cobalt can span decades rather maximum 90-days endured by the 17-dialysis patients in 1975-6 or Cardno ChemRisk's 10 subjects.^{62,188,224-}
184 ^{235,237} Furthermore, the 17-dialysis patients that Cardno ChemRisk theorizes tolerated high blood cobalt (three actually developed deafness) underwent dialysis trice weekly
185 and therefore were not exposed incessantly to cobalt as are patients exposed through a malfunctioning prosthetic implant.^{62,235}

186 Contradicting Cardno ChemRisk's mercenary theoretical work there are now a plethora of arthroprosthetic cobaltism case reports showing that when blood
187 cobalt exceeds 100 ppb extreme illness results in death, heart transplantation, psychiatric decompensation, blindness, deafness, thyroid failure, and severe peripheral
188 neuropathy.^{3,126-132,134,238-241} Additionally, there are now multiple case series and case reports indicating that serious systemic illness can result once blood cobalt levels are
189 ≥ 7 ppb from an arthroprosthetic source.^{3,15,107,133,146,147,242-244} These case reports likely represent a minute fraction of those patients actually experiencing arthroprosthetic
190 cobaltism because awareness of the condition is so limited among medical providers and the public, a point reinforced by Umar et al in their 2019 review of arthroprosthetic
191 cobalt myocardial pathology (CMP):²⁴⁴

Cobalt-related CMP has been reported in a relatively very low number of cases of metal hip arthroplasty. However, it may be the tip of the iceberg, as for every published case report, there are likely hundreds of similar severity unrecognized or recognized and not reported cases. A delay in diagnosis may lead to significant morbidity

194 Umar's conclusion is an echo of that of Gessner's systematic review of the literature on Arthroprosthetic Cobaltism in 2015:¹³

DISCUSSION

Our study identified 25 cases of reported arthroprosthetic cobaltism that occurred since the initial report during 2001. Case reports have accelerated recently and have occurred from 8 countries. Despite the relatively widespread distribution, all but 2 US cases have originated from Alaska, suggesting the true scope of the problem has gone largely unreported. This likely has resulted from a combination of several factors including the slow onset, the protean symptoms that may mimic many different conditions, lack of uniform screening strategies for at-risk patients, and lack of awareness of arthroprosthetic cobaltism among surgeons and primary care physicians.

195

196

4. FDA pre and post market maleficence is delaying the recognition and remediation of Arthroprosthetic Cobaltism

197

198

199

200

201

202

203

204

205

206

207

208

209

210

211

212

In 2012 my clinical experience indicated that arthroprosthetic cobaltism was common in patients with metal-on-metal hips beyond the recalled J&J ASR. I was surprised that the FDA at that time ignored this problem and excluded me from its expert panel addressing growing public concern of premature failure of this class of hip that was placed in about a million Americans. My 2012 manuscript on the frequency of the problem in Alaskans with metal-on-metal hips (appendix B) was submitted to the docket of the 2012 expert panel and was ignored. The FDA did not mandate a monitoring program for patients with metal-on-metal hips and the companies that made them were allow to silently remove them from the market. Three AAOS nominated surgeons that were allowed to participate on the 2012 panel soon thereafter wrote a review article in a AAOS-supported journal suggesting that metal-on-metal hips were safe.²⁴⁵ It was not until 2014 that a consciences opinion of the AAOS, Hip and Knee society, and the American Association of Knee and Hip Surgeons recommended a monitoring suggestion for the million Americans implanted with no longer marketed metal-on-metal hips.¹⁸⁵ These recommendations are seldom systematically followed by American orthopedic surgeons and the FDA continues to post only vague recommendations for monitoring patients with no longer marketed metal-on-metal hips.²⁴⁶ Delayed inaction by the FDA concerning the now well documented periprosthetic and systemic cobalt-chromium metallosis has harmed hundreds of thousands of Americans.¹² Systematic literature review by Gessner indicates that arthroprosthetic cobaltism is likely a spectrum illness with a large American at-risk population.¹³ My exclusion from the 2019 expert panel gives me cause for concern that the FDA's pattern of placing the health of the arthroprosthetic industry above that of 20 million Americans with implanted CoCr hip, shoulder, and knee parts continues. My interactions with the FDA, the AAOS, Orthopedic Journals, and the committees that accept presentations for Orthopedic meetings confirms that conflict-of interest is the driving force of commercial, academic, and regulatory malfeasance leading to the under-recognition, propagation, and delayed remediation of a silent epidemic of periprosthetic and systemic complications of arthroprosthetically generated cobalt-chromium metallosis with an American at-risk population of 20 million.

5. Industry's willful blindness to Arthroprosthetic Cobaltism is compounding the problem

213

214

215

Rather than recognizing and remediating its CoCr metallosis liabilities industry appears to be intent on a cover-up, at least that was the approach of J&J during its bellwether trial *Kransky v J&J* concerning DePuy ill-starred MoM ASR hip ... per Bloomberg:

\$5 Million

Paustenbach said his firm ChemRisk Inc. has billed DePuy at least \$5 million over the past 18 months. He was part of a team of 40 people who spent thousands of hours studying medical literature and found virtually no research on the effects of cobalt prior to the ASR recall.

"What systemic health effects have you found?" J&J attorney Alexander Calfo asked Paustenbach.

"I saw none," Paustenbach said.

216

217

218

219

220

221

222

223

Paustenbach's prior retrospective "pseudoscience" concerning asbestos and his mercenary behavior to his critics has resulted in the resignation of the entire editorial board of a respected Occupational and Environmental Toxicology Journal. It appears that Paustenbach's companies Cardno ChemRisk LLC and Exponent exist for the sole purpose to manufacture misinformation "proving" that substances well known to be toxic are not for the purpose of defending industry, work for which Cardno ChemRisk LLC and Exponent are paid exorbitant fees. Most concerning is that the medical journal publishing behemoth Francis & Taylor appears to willing to legitimize Cardno ChemRisk LLC and Exponent's "research" by strong-arming editorial boards to publish Exponent's and Cardno ChemRisk's work:

<https://www.propublica.org/article/sudden-shift-at-a-public-health-journal-leaves-scientists-feeling-censored>

224

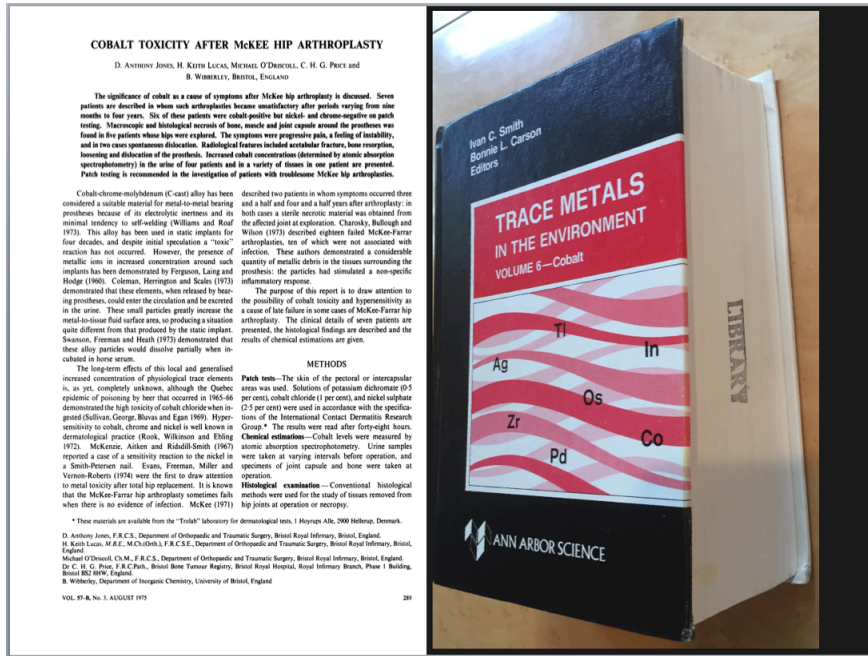225

226

227


Any legitimate research effort into the known deleterious effects of arthroprosthetically generated cobalt could not have missed the 1981 US government commissioned tome on Cobalt toxicity edited by Smith and Carson⁴¹ and the seminal 1975 report of periprosthetic and systemic cobalt toxicity in a series of patients with periprosthetic CoCr metallosis from McKee-Farrah Metal-on-Metal hip replacement.²⁰ The mercenary literature produced by Paustenbach and his co-conspirators fails to cite either.^{188,224-234,237}

Dr. Tower's Briefing to Dr. Raj Rao, Chairperson FDA Medical Devices Advisory Committee
Expansion of Dr. Tower's 8.5 minutes of Open Public Testimony, November 13 2019



228
229
230
231

Alone and ill, without force multiplier of \$5 million and 40 confederates, I found both in December 2007 (6 years before Paustenbach's, Exponent's, and Cardno ChemRisk LLC's mercenary exercise) after 3 months of disability from my first cobalt-toxic decompensation for my own right ASR XL.^{3,10,11,16}



LEFT:
My DePuy ASR Metal-on-Metal hip after 42 months of service. The gap between the head and the socket at the anterior-lateral quadrant indicated wear 1,000 times predicted, explaining my blood cobalt level of 122 ppb and joint fluid cobalt of 3200 ppb. My joint capsule was necrotic and my revised hip therefore unstable resulting in 9 dislocations.
RIGHT:
Magnified view show unanticipated wear and damage to the surface of the femoral head.

232
233
234
235
236
237
238
239

It was apparent enough to me, then, based only on these two general and specific seminal publications on arthroprosthetic cobalt toxicity that I was cobalt poisoned.^{20,41} The psychiatric nature of my decompensation made it impossible at that time to convince my family, friends, and medical providers that I was suffering from metal poisoning rather than *mood disorder not otherwise specified*.¹¹ My blood-cobalt level then was 122 times that indicating unsafe industrial exposure,^{3,10,11,16} yet was only a fraction of what Paustenbach and his confederates *theorize* to be a toxic blood-cobalt threshold of 300 ppb.^{188,224,226-233,237}

At the same time Cardno ChemRisk employed 40 confederates and charged DePuy 5 million dollars to show that the medical literature indicated that a blood cobalt level of < 300 ppb from arthroprosthetically generated CoCr metallosis is safe,^{228,232} Gessner and two rising second-year-medical-students found 25 well-documented cases of arthroprosthetic cobaltism:²¹⁹

A Systematic Review of Systemic Cobaltism After Wear or Corrosion of Chrome-Cobalt Hip Implants

Bradford D. Gessner, MD, MPH,* Thomas Steck, BS,† Erik Woelber, MSc,‡ and Stephen S. Tower, MD‡

240

Objectives: We sought to synthesize data on systemic arthroprosthetic cobaltism, a recently described syndrome that results from wear or corrosion of chrome-cobalt hip components.

Methods: We conducted a systematic literature review to identify all reported cases of systemic arthroprosthetic cobaltism. To assess the epidemiologic link between blood cobalt levels (B[Co]), we developed a symptom scoring tool that evaluated 9 different symptom categories and a category of medical utilization.

Results: We identified 25 patients reported between 2001 and 2014 with a substantial increase in case reports over the past 3 years. Symptoms were diverse and involved the hip (84%), cardiovascular system (60%), audiovestibular system (52%), peripheral motor-sensory system (48%), thyroid (48%), psychological functioning (32%), visual system (32%), and the hematological, oncological, or immune system (20%). The mean latency from implantation to presentation or revision was 41 months (range, 9–99 months). The mean B[Co] was 324 µg/L and 4 patients had levels less than 20 µg/L. The B[Co] but not blood chromium level was highly associated with a quantitative measure of overall symptom severity (r^2 , 0.81; $P < 0.001$). Mean B[Co] and symptom scores were substantially higher in patients with revisions of failed ceramic-on-ceramic prostheses than those with primary metal-on-metal prostheses.

Conclusions: Systemic arthroprosthetic cobaltism is an increasingly recognized complication of wear or corrosion of chrome-cobalt hip implants, may involve a large number of organ systems, and may occur with relatively low B[Co]. There is an urgent need to better define the overall scope of the problem and to develop screening and management strategies.

Key Words: arthroplasty, cobalt, cobaltism, hip, hip replacement

(*J Patient Saf* 2015;00: 00–00)

241

242

243

244

245

246

247

248

249

250

251

252

253

254

255

256

257

258

259

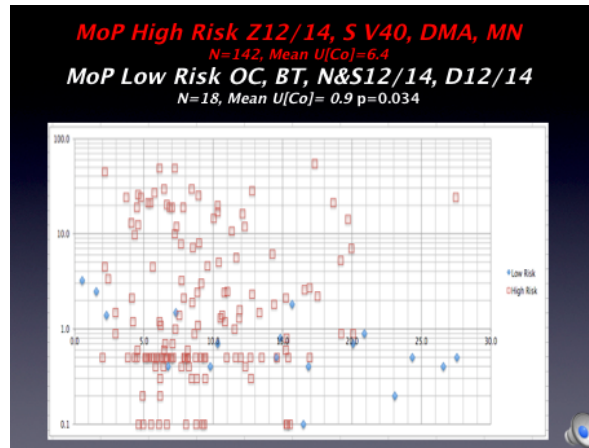
260

Exceptional to Cardno ChemRisk's claim that a blood cobalt of < 300 ppb is safe Gessner et al found 4 cases reports of neurologic and cardiac toxicity in subjects with a blood cobalt level of < 20 ppb from arthroprosthetic. Gessner et al also noted that the severity of neurologic and cardiac illness correlated with the degree of elevation in blood cobalt level.²¹⁹ My clinics ongoing work screening patients with any CoCr arthroprosthetic implant indicates that sensitive individuals exposed to arthroprosthetically generated cobalt may develop neurologic symptoms and significant brain hypometabolism by FDG-PET-Brain-Scan once their blood cobalt level equals or exceeds the 95 percentile blood-cobalt level (0.4 ppb) of subjects without exposure to cobalt through industry, by ingestion, or by having an CoCr arthroprosthetic implant

Also counter to Cardno ChemRisk's mercenary conclusions is a study of brain MRIs in 29 patients with asymptomatic hip resurfacing implants with mean blood cobalt of 1.72 ppb (1.1-6.0) compared with 29 patients with hip replacements with mean blood cobalt of 0.38 ppb (0.33-0.50), the groups were matched and studied at a mean period of 8 years post arthroplasty.²⁴⁷ The group with modest blood cobalt elevation showed significantly diminished brain volume in the optic pathways and the basal ganglia compared to the control group with normal blood cobalt level.²⁴⁷ The same subjects' heart function was compared by echocardiography, the patients with modest blood elevation show significantly diminished heart function compared to the group with normal blood levels.²⁴⁸ It is critical to note that the 29 patients with resurfaced hips, abnormal brain volumes, and abnormal heart function, had a mean blood cobalt level 170 times²⁴⁷ lower than Paustenbach's safety threshold of 300 ppb.²²⁸

5. Frequency and Severity of Corrosion at modular junctions of CoCr parts relates to taper design and tolerance

In my 40-year surgical experience with hip arthroplasty, surgery; clinically significant, gross corrosion, resulting in periprosthetic and systemic toxicity, is almost never seen in some implants yet is commonly seen in others. Clinically significant corrosion resulting in periprosthetic or systemic toxicity is a design and materials issue: Largely preventable by optimal material selection and prosthetic design. Systematic study for my practice over the past 4 years indicates that Zimmer's 12/14 and Stryker's V40 CrCo femoral heads commonly corrode over time. Many patients that experiencing this problem have periprosthetic and systemic morbidity sometimes severe enough to warrant revision hip surgery to replace corroding or wearing CrCo parts with safe plastic, ceramic, TiAlV, or FeCrNi alternatives.



261
262
263

The Y-axis is urine cobalt in ppb; the X-axis is years of hip implantation. The blue diamond data-points with urine-cobalt of < 1 ppb are nearly all Osteonics' C-Taper LFIT CoCr head on TiAlV alloy uncemented stem trunnions



264
265
266
267

These Osteonics stems were both in situ for > 15 years in highly active young men. There is no apparent corrosion in the bores of the CoCr heads. This likely relates to robust design of the C-Taper, tight tolerance of taper angle match between the head-bore and stem-trunnion and the smooth finish of the trunnion²⁴⁹⁻²⁵¹

268
269
270
271
272
273
274
275
276
277
278
279
280

Whether or not that corrosion will be periprosthetically or systemically adverse hinges on at least four factors: the toxicity of the corrosion byproducts (periprosthetically and systemically), the sensitivity of the patient to the corrosion byproducts (periprosthetically and systemically), the biomechanical consequences of corrosion, and the severity and extent of the process. Severe corrosion commonly occurs at the TiAlV stem-cement interfaces resulting in pain and early loosening of components that lead to the abandonment of that alloy for cemented stem application but I am not aware that either systemic toxicity or hypersensitivity has been reported from TiAlV corrosion debris but there has been at least one case of Vanadium neurotoxicity from wear of a TiAlV acetabular shell by ceramic.^{105,106} ²⁵² Minor corrosion is commonly noted on the surface of explanted FeCrNi Exeter polished stems but this is generally without periprosthetic or mechanical consequence other than rare clinically significant immune reaction due to the nickel exposure.^{104,253} The severe corrosion I found the cement-stem interface of Zimmer polished CoCr Heritage stems in patients A-C did not result in radiographic or clinical loosening of the stems (the stems were difficult to extract) but the cobalt and chromium liberated by the corrosion resulted in symptoms at the hips and systemic poisoning of the patients confirmed by FDG-PET brain scans. A series of 13 failed Zimmer CPT polished CoCr stems revised for progressive hip symptom was recently reported, all had gross corrosion at the stem-cement interface.¹⁰⁰ DePuy's polished CoCr Ultima stem frequently fails by the same mechanism, particularly when mated to a metal-on-metal articulation.¹⁰³

281 Periprosthetic CoCr metallosis produced by wear or corrosion of CoCr articular components (heads or sockets) or at the taper
282 junctions (Figure 1) of articular and non-articular implants (stems, necks, or trays) may result in painful or painless periprosthetic tissue
283 inflammation, necrosis and pseudotumor formation.^{3,140,141,196,254,255} Collectively, these radiographic findings and symptoms are called
284 Adverse-Reaction-to-Metal-Debris (ARMD).¹⁴¹ Patients may also react in an immune fashion to CoCr implants by direct attack of
285 leukocytes resulting in ARMD and systemically circulated cobalt in the absence of significant implant wear or taper corrosion.²⁵⁶ The
286 histopathology of patients with CoCr symptomatic ARMD is highly variable.^{124,203,257,258} In my experience, and in that reported by others,
287 patient with an hyper-acute presentation with months of implantation are more likely to have florid inflammatory infiltrates (ALVAL lesions)
288 whereas the majority of patient that develop ARMD have an indolent presentation and generally a mixed histopathologic response of mild
289 chronic inflammation, a macrophage response, varying degrees of tissue necrosis with ulcerations of the synovial
290 membrane.^{20,192,194,195,257,259}

291 Most of the publications addressing the symptoms, laboratory abnormalities (elevated blood and urine cobalt levels), imaging
292 findings, gross and histopathologic findings at revision surgery of CoCr periprosthetic metallosis report on hip resurfacings failed due to
293 wear, or Metal-on-Metal total hips in which the CoCr metallosis may be generated by wear of the articular surfaces or corrosion at taper
294 junctions.^{141-143,258,260-268} The notable failure of the Styker Rejuvenate with its modular CoCr neck that was prone to corrosion at the distal
295 junction were it dove-tailed into a TiAlV alloy stem, and at its proximal junction regardless of whether it was mated to a CoCr or ceramic
296 head informed me that ARMD and cobaltism were not unique to Metal-on-Metal articulations. The Rejuvenate was a popular implant in
297 Anchorage; fortunately I never implanted one but revised many. Because the implant was formally recalled by Stryker July of 2012 and
298 the recall program recommend a systematic screen program for cobalt levels and imaging of any symptomatic implant I became aware
299 that the patients with failed Rejuvenate implants were experiencing the same problems as the patients with failed Metal-on-Metal hips. If
300 anything the patient's with failed Rejuvenates often had more florid ARMD than the MoM patients (by symptoms) although their blood and
301 urine cobalt levels were generally an order of magnitude less that those MoM patients whose metallosis related to excessive wear of their
302 articular surfaces. Other investigators have confirmed that corrosion generated cobalt-chrome metallosis (tapers) being more toxic
303 periprosthetically than wear generated cobalt-chrome metallosis (edge loading of metal-on-metal hip articulations).^{2,169,191}

304 Clinically, cemented FeCrNi stems with Monoblock or Modular FeCrNi heads articulating on polyethylene have superior
305 survivorship in single institution series and in the National Joint Registry of England-Wales in the form of the matt finished Charley stem
306 or the polished Exeter stem compared nearly all other contemporary bearing couples and femoral stem materials. The Charnley and
307 Exeter hips utilizing FeCrNi stems and head articulating on either cross-linked or standard polyethylene are among the few contemporary
308 hips that meet the NICE criteria of an annualized failure rate of < 0.5% per year.^{82,90,269,270}

309 Systemic cobalt-toxicity (cobaltism) most commonly affects the nervous, endocrine and cardiovascular systems. Profound
310 deafness, blindness, peripheral neuropathy, thyropathy, polycythemia, cardiac failure, and death may result in extreme cases.^{3,13,20,41-43}
311 Reports of such severe toxicity are limited to two circumstances: revision of a fractured ceramic hip implant to a CoCr femoral head, or
312 when a CoCr ball and CoCr socket articulate (Metal-on-Metal-Hip).¹³ The incidence of the former is rare compared to the latter: about 2
313 million Metal-on-Metal-Hips were implanted.^{12,13,271} A subtler presentation of neurologic, psychiatric, and constitutional maladies, easily
314 confused with aging, and similar to the vocational manganese toxicity, results from nominal cobalt exposure from wear or corrosion of
315 modular CoCr implants, or CoCr articular surfaces.^{1,3,13,107,140,146,255,272}

316 F¹⁸DG-PET-CT-Brain-Scan has become instrumental in early detection and monitoring of neurodegenerative disease and
317 neurotoxin exposure.²⁷³⁻²⁷⁸ Visual interpretation of SPECT and PET imaging was described in 1991 to identify regions of brain injury

318 resulting from vocational pesticide and solvent exposure.²⁷⁸ Subsequently, FDA approved software was developed that quantitatively
319 compares patient F¹⁸DG-PET-CT-Brain-Scan data to age-gender norms assigning a T-score to 47 cluster-regions.²⁷⁹ Such software
320 provides a reproducible and objective dataset without the inter-observer variability or basis inherent with the earlier technology.^{278,279}

321

Patient Vignettes

322 Patient 1: 83 year-old retired engineer with 6-year history of a 36 mm CoCr right Metal-on-Plastic-Hip (Stryker, Kalamazoo MI) presented with
323 new onset hip pain and weakness, bilateral restless leg syndrome, difficulty sleeping, sleep apnea, fatigue, exertional-dyspnea, deafness, and
324 retinopathy. Screening blood and urine cobalt were 4.8 and 49.1 ppb and his Cobaltism-Symptom-Inventory-Score was 5/14. Metal-Suppression-Hip-
325 MRI confirmed ARMD including incomplete detachment of the gluteus medius tendon from the greater trochanter. Initial F¹⁸DG-PET-CT-Brain-Scan
326 had a summed score for 90 regions of -228.4 with 22 hypometabolic-cluster-regions. CT showed mild symmetric prominence of sulci. At surgery there
327 was marked corrosion at the trunnion of the stem and the bore of the head and the peri-prosthetic tissues were inflamed and thickened. Cobalt level of
328 right joint fluid collected at time of surgery was 1,000 ppb. Repeat PET scan 17 months post revision showed a summed score for 34 regions of -88.7
329 with 6 hypometabolic cluster-regions). Post-revision blood and urine cobalt fell to 0.5 and 2.5 ppb.

330 Patient 2: 67 year-old retired businesswoman with 12-year history of left CoCr Pinnacle Metal-on-Metal-Hip (DePuy, Warsaw IN) presented
331 with hip pain, forgetfulness, fatigue, and depression. Blood and urine cobalt were 0.9 and 1.6 ppb and her Cobaltism-Symptom-Inventory-Score was
332 3/14. Metal suppression MRI of hip confirmed ARMD. Initial F¹⁸DG-PET-CT-Brain-Scan showed no structural abnormalities with 134 hypometabolic
333 regions with summed score of -381.7 with 28 hypometabolic cluster-regions. The patient was treated with oral OTC N-acetyl-Cysteine,²⁸⁰ and revision of
334 the CoCr-socket-liner to plastic, and revision of the CoCr-head to ceramic. Corrosion was found at taper interface between the TiAlV stem and CoCr
335 head at revision-surgery and the periprosthetic tissue was inflamed and thickened, joint-fluid-cobalt was 160 ppb. At 13 months post-revision repeat
336 scan had 87 hypometabolic regions with score of -229.6 and 18 hypometabolic cluster-regions. Blood and urine cobalt declined to 0.2 and 0.4 ppb.

337 Patient 3: A 57 year-old retired-Army-Colonel with a left revision Ceramic-on-Plastic-Hip utilizing a modular CoCr-socket-liner for a "Modular-
338 Dual-Mobility" (Stryker, Kalamazoo MI) articulation.²⁵⁵ These components replaced a recalled Rejuvenate stem (Stryker, MI) that utilized a modular CoCr
339 neck, five years previously, because the patient had symptomatic cobaltism, ARMD, and blood-cobalt of 19 ppb. After initial resolution of hip and
340 neurologic symptoms blood-cobalt and urine-cobalt climbed to 1.5 and 9.9 ppb, and the patient's hip, neurologic, cardiac symptoms reoccurred.
341 Cobaltism-Symptom-Inventory-Score was 7/14. CT imaging showed mild left temporal-parietal sulci prominence from an IED explosion that excluded
342 him from the primary study group. Operative findings noted corrosion on the backside of CoCr Dual-Mobility-Acetabular-Liner, and periprosthetic fluid
343 had cobalt of 220 ppb. Pre-revision F¹⁸DG-PET-CT-Brain-Scan found 40 hypometabolic regions with score of -96.6 and 4 hypometabolic cluster-regions.
344 8-months post-revision repeat scan showed 19 hypometabolic regions, a score of -42 and 2 hypometabolic cluster-regions. Blood-cobalt and urine-
345 cobalt declined to < 0.2 and 0.2 ppb.

346 Patient 4: 77 year-old retired teacher with right Metal-on-Plastic-Hip (Zimmer, IN) of 9 years duration presented with progressive hip pain,
347 fatigue, forgetfulness, retinopathy, and decreased reading speed and comprehension. Screening Cobaltism-Symptom-Inventory-Score was 5/10 and
348 blood-cobalt and urine-cobalt were 4.9 and 10.6 ppb. Metal-suppression-hip-MRI showed a cystic ARMD. Initial F¹⁸DG-PET-CT-Brain-Scan revealed no
349 structural abnormality with 25 hypometabolic regions with summed score of -54 and 5 hypometabolic cluster-regions, two years later a follow-up scan
350 showed progression with 25 hypometabolic regions with summed score of -56.4 and 8 hypometabolic cluster-regions. Because of progression of hip
351 pain, neurologic and constitutional symptoms, and progressive brain hypometabolism by F¹⁸DG-PET-CT-Brain-Scan revision surgery was elected. The
352 cemented CoCr Heritage stem (Zimmer, Warsaw IN) was highly corroded, and the periprosthetic tissues were inflamed and thickened, and
353 periprosthetic fluid cobalt was 390 ppb. At 5-months post-revision blood-cobalt and urine-cobalt have declined to 0.7 and 1.0 ppb and the patient's hip
354 pain, neurologic and constitutional symptoms have resolved.

355

- 356 1. Woelber E, Van Citters DW, Steck T, Glass GA, Tower S. Explant Analysis from a Patient Exhibiting Rapid
357 Acceleration of Parkinson Disease Symptoms and Hypercobaltemia Following Metal-on-Metal Total Hip Arthroplasty.
358 JBJS Case Connect 2016;6:e45.
- 359 2. Currier JH, McHugh DJ, Tower DR, Kennedy FE, Van Citters DW. Gouge features on metal-on-metal hip
360 bearings can result from high stresses during rim contact. Tribology International 2012.
- 361 3. Tower SS. Arthroprosthetic cobaltism: neurological and cardiac manifestations in two patients with metal-on-metal
362 arthroplasty: a case report. J Bone Joint Surg Am 2010;92:2847-51.
- 363 4. Tower SS, Currier JH, Currier BH, Lyford KA, Van Citters DW, Mayor MB. Rim cracking of the cross-linked
364 longevity polyethylene acetabular liner after total hip arthroplasty. J Bone Joint Surg Am 2007;89:2212-7.
- 365 5. Margolis HS, Hardison HH, Bender TR, Dallman PR. Iron deficiency in children: the relationship between
366 pretreatment laboratory tests and subsequent hemoglobin response to iron therapy. Am J Clin Nutr 1981;34:2158-68.
- 367 6. Tower SS, Pratt WB. Spondylolysis and associated spondylolisthesis in Eskimo and Athabaskan populations. Clin
368 Orthop Relat Res 1990:171-5.
- 369 7. Tower SS, Beals RK. Fractures of the femur after hip replacement: the Oregon experience. Orthop Clin North Am
370 1999;30:235-47.
- 371 8. Beals RK, Tower SS. Periprosthetic fractures of the femur. An analysis of 93 fractures. Clin Orthop Relat Res
372 1996:238-46.
- 373 9. Tower SS, Beals RK, Duwelius PJ. Resonant frequency analysis of the tibia as a measure of fracture healing.
374 Journal of orthopaedic trauma 1993;7:552-7.
- 375 10. Epidemiology A. Cobalt Toxicity in Two Hip Replacement Patients. State of Alaska Epidemiology Bulletin 2010.
- 376 11. Sotos JG, Tower SS. Systemic disease after hip replacement: aeromedical implications of arthroprosthetic
377 cobaltism. Aviation, space, and environmental medicine 2013;84:242-5.
- 378 12. Tower S. Hip Metallosis and Corrosion-A Million Harmed Due to FDA Inaction. J Patient Saf 2016.
- 379 13. Gessner BD, Steck T, Woelber E, Tower SS. A Systematic Review of Systemic Cobaltism After Wear or
380 Corrosion of Chrome-Cobalt Hip Implants. J Patient Saf 2015.
- 381 14. Estey MP, Diamandis EP, Van Der Straeten C, Tower SS, Hart AJ, Moyer TP. Cobalt and chromium measurement
382 in patients with metal hip prostheses. Clinical chemistry 2013;59:880-6.
- 383 15. Tower SS. Arthroprosthetic cobaltism associated with metal on metal hip implants. Bmj 2012;344:e430.
- 384 16. Tower S. Arthroprosthetic cobaltism: identification of the at-risk patient. Alaska Med 2010;52:28-32.
- 385 17. Kelly T, Bauer S, Tower S. Power, Credibility and Expertise in a Colonized Medical Discourse. 2013.
- 386 18. Estey MP, Diamandis EP, Van Der Straeten C, Tower SS, Hart AJ, Moyer TP. Cobalt and Chromium
387 Measurement in Patients with Metal Hip Prostheses. Clinical chemistry 2012.
- 388 19. Kavanagh KT, Tower SS, Saman DM. A Perspective on the Principles of Integrity in Infectious Disease Research.
389 J Patient Saf 2016;12:57-62.
- 390 20. Jones DA, Lucas HK, O'Driscoll M, Price CH, Wibberley B. Cobalt toxicity after McKee hip arthroplasty. J Bone
391 Joint Surg Br 1975;57:289-96.
- 392 21. Gill HS, Grammatopoulos G, Adshead S, Tsiologiannis E, Tsiroidis E. Molecular and immune toxicity of CoCr
393 nanoparticles in MoM hip arthroplasty. Trends in molecular medicine 2012;18:145-55.
- 394 22. Rae T. The toxicity of metals used in orthopaedic prostheses. An experimental study using cultured human
395 synovial fibroblasts. J Bone Joint Surg Br 1981;63-B:435-40.
- 396 23. Smith IC, Carson BL. Volume 6-Cobalt An Apraisal of Environmental Exposure. 1st ed. Ann Arbor: Ann Arbor
397 Science; 1981.
- 398 24. Hart A, Skinner J, Winship P, et al. Circulating levels of cobalt and chromium from metal-on-metal hip
399 replacement are associated with CD8+ T-cell lymphopenia. Journal of Bone & Joint Surgery, British Volume 2009;91:835-
400 42.
- 401 25. Dunstan E, Ladon D, Whittingham-Jones P, Carrington R, Briggs TW. Chromosomal aberrations in the peripheral
402 blood of patients with metal-on-metal hip bearings. J Bone Joint Surg Am 2008;90:517-22.
- 403 26. Whittingham-Jones PM, Dunstan E, Altaf H, Cannon SR, Revell PA, Briggs TW. Immune responses in patients
404 with metal-on-metal hip articulations: a long-term follow-up. J Arthroplasty 2008;23:1212-8.
- 405 27. Grice HC, Heggteit HA, Wiberg GS, Van Petten G, Willes R. Experimental cobalt cardiomyopathy: correlation
406 between electrocardiography and pathology. Cardiovasc Res 1970;4:452-6.
- 407 28. Heggteit HA, Grice HC, Wiberg GS. Cobalt cardiomyopathy. Experimental basis for the human lesion. Pathol
408 Microbiol (Basel) 1970;35:110-3.
- 409 29. Mohiuddin SM, Taskar PK, Rheault M, Roy PE, Chenard J, Morin Y. Experimental cobalt cardiomyopathy. Am
410 Heart J 1970;80:532-43.

- 411 30. Rona G. Experimental aspects of cobalt cardiomyopathy. *Br Heart J* 1971;33:Suppl:171-4.
- 412 31. Alexander CS. Cobalt-beer cardiomyopathy. A clinical and pathologic study of twenty-eight cases. *Am J Med*
- 413 1972;53:395-417.
- 414 32. Olsen EG. Histochemical, ultrastructural and structural changes in primary cardiomyopathy and in cobalt
- 415 cardiomyopathy. *Postgrad Med J* 1972;48:760-2.
- 416 33. Wojcicki J, Rozewicka L, Kadykow M. Effects of essential phospholipids (EPL) on experimental cobalt-induced
- 417 cardiomyopathy. *Arzneimittelforschung* 1973;23:1070-4.
- 418 34. Riahi H, Burman SO, Casale T, et al. An experimental model of cardiomyopathy. *Surg Forum* 1976;27:278-80.
- 419 35. Sandusky GE, Henk WG, Roberts ED. Histochemistry and ultrastructure of the heart in experimental cobalt
- 420 cardiomyopathy in the dog. *Toxicol Appl Pharmacol* 1981;61:89-98.
- 421 36. Unverferth DV, Croskery RW, Leier CV, et al. Canine cobalt cardiomyopathy: a model for the study of heart
- 422 failure. *Am J Vet Res* 1983;44:989-95.
- 423 37. Centeno JA, Pestaner JP, Mullick FG, Virmani R. An analytical comparison of cobalt cardiomyopathy and
- 424 idiopathic dilated cardiomyopathy. *Biol Trace Elem Res* 1996;55:21-30.
- 425 38. Frustaci A, Magnavita N, Chimenti C, et al. Marked elevation of myocardial trace elements in idiopathic dilated
- 426 cardiomyopathy compared with secondary cardiac dysfunction. *J Am Coll Cardiol* 1999;33:1578-83.
- 427 39. Karovic O, Tonazzini I, Rebola N, et al. Toxic effects of cobalt in primary cultures of mouse astrocytes.
- 428 Similarities with hypoxia and role of HIF-1alpha. *Biochem Pharmacol* 2007;73:694-708.
- 429 40. Stewart WJ, Johansen JL, Liao JC. A non-toxic dose of cobalt chloride blocks hair cells of the zebrafish lateral
- 430 line. *Hear Res* 2017;350:17-21.
- 431 41. Smith IC, Carson BL. *Trace Elements in the Environment Volume 6- Cobalt*. 1981.
- 432 42. Catalani S, Rizzetti MC, Padovani A, Apostoli P. Neurotoxicity of cobalt. *Hum Exp Toxicol* 2011.
- 433 43. Simonsen LO, Harbak H, Bennekou P. Cobalt metabolism and toxicology--a brief update. *Sci Total Environ*
- 434 2012;432:210-5.
- 435 44. Visuri TI, Pukkala E, Pulkkinen P, Paavolainen P. Cancer incidence and causes of death among total hip
- 436 replacement patients: a review based on Nordic cohorts with a special emphasis on metal-on-metal bearings. *Proc Inst Mech*
- 437 *Eng H* 2006;220:399-407.
- 438 45. Visuri T, Koskenvuo M. Cancer risk after Mckee-Farrar total hip replacement. *Orthopedics* 1991;14:137-42.
- 439 46. Lison D, van den Brule S, Van Maele-Fabry G. Cobalt and its compounds: update on genotoxic and carcinogenic
- 440 activities. *Crit Rev Toxicol* 2018:1-18.
- 441 47. Sighinolfi GL, Artoni E, Gatti AM, Corsi L. Carcinogenic potential of metal nanoparticles in BALB/3T3 cell
- 442 transformation assay. *Environ Toxicol* 2016;31:509-19.
- 443 48. Judson GJ, McFarlane JD, Mitsioulis A, Zviedrans P. Vitamin B12 responses to cobalt pellets in beef cows.
- 444 *Australian veterinary journal* 1997;75:660-2.
- 445 49. Hill JM, Lajous J, Sebastian FJ. Cobalt therapy in anemia. *Texas state journal of medicine* 1955;51:686-90.
- 446 50. Gardner FH. The use of cobaltous chloride in the anemia associated with chronic renal disease. *J Lab Clin Med*
- 447 1953;41:56-64.
- 448 51. Gottwald G. [Cobalt therapy of anemia in ambulant practice]. *Das Deutsche Gesundheitswesen* 1953;8:1092-4.
- 449 52. Schmoger R. [Cobalt therapy of the anemia in premature infant]. *Archiv fur Kinderheilkunde* 1953;146:238-47.
- 450 53. Bockhorn K. [The treatment of hypochromic anemia with iron and cobalt]. *Der Praktische Arzt* 1952;6:479-82.
- 451 54. Heilmeyer L. [Hypochromic anemia refractory to iron and responding to cobalt therapy]. *Schweizerische*
- 452 *medizinische Wochenschrift* 1951;81:1240-1.
- 453 55. Goldeck H, Groth H. [Anemia therapy with complex cobalt salts]. *Therapie der Gegenwart* 1951;90:371-4.
- 454 56. Greif S, Wennig F. [Cobalt, blood regeneration and the treatment of anemia]. *Wiener klinische Wochenschrift*
- 455 1951;63:657-9.
- 456 57. Wolff H, Barthel S. [Anemia therapy with cobalt compounds]. *Munch Med Wochenschr* 1951;93:467-72.
- 457 58. Esser H, Lammler G. [Cobalt therapy of secondary anemia in chronic infections and tumors]. *Medizinische*
- 458 *Monatsschrift* 1951;5:93-5.
- 459 59. Berk L, Burchenal JH, Castle WB. Erythropoietic effect of cobalt in patients with or without anemia. *The New*
- 460 *England journal of medicine* 1949;240:754-61.
- 461 60. La Grutta A, Amato GM, Fedele S, Vitaliti S. [Chronic cobalt poisoning. Presentation of a clinical case of
- 462 cardiomyopathy]. *Minerva Pediatr* 1984;36:691-7.
- 463 61. Manifold IH, Platts MM, Kennedy A. Cobalt cardiomyopathy in a patient on maintenance haemodialysis. *Br Med J*
- 464 1978;2:1609.
- 465 62. Duckham JM, Lee HA. The treatment of refractory anaemia of chronic renal failure with cobalt chloride. *Q J Med*

- 1976;45:277-94.
- 467 63. Licht A, Oliver M, Rachmilewitz EA. Optic atrophy following treatment with cobalt chloride in a patient with
468 pancytopenia and hypercellular marrow. *Isr J Med Sci* 1972;8:61-6.
- 469 64. Sederholm T, Kouvalainen K, Lamberg BA. Cobalt-induced hypothyroidism and polycythemia in lipid nephrosis.
470 *Acta Med Scand* 1968;184:301-6.
- 471 65. Keegan GM, Learmonth ID, Case CP. A systematic comparison of the actual, potential, and theoretical health
472 effects of cobalt and chromium exposures from industry and surgical implants. *Crit Rev Toxicol* 2008;38:645-74.
- 473 66. Barceloux DG. Cobalt. *J Toxicol Clin Toxicol* 1999;37:201-6.
- 474 67. Lauwerys R, Lison D. Health risks associated with cobalt exposure--an overview. *Sci Total Environ* 1994;150:1-6.
- 475 68. Jarvis JQ, Hammond E, Meier R, Robinson C. Cobalt cardiomyopathy. A report of two cases from mineral assay
476 laboratories and a review of the literature. *J Occup Med* 1992;34:620-6.
- 477 69. Kurppa K, Hietanen E, Klockars M, et al. Chemical exposures at work and cardiovascular morbidity.
478 Atherosclerosis, ischemic heart disease, hypertension, cardiomyopathy and arrhythmias. *Scand J Work Environ Health*
479 1984;10:381-8.
- 480 70. Kennedy A, Dornan JD, King R. Fatal myocardial disease associated with industrial exposure to cobalt. *Lancet*
481 1981;1:412-4.
- 482 71. Alexandersson R AJ. Studies on effects of exposure to cobalt. . 1980:1-21.
- 483 72. Bhardwaj N, Perez J, Peden M. Optic neuropathy from cobalt toxicity in a patient who ingested cattle magnets.
484 *Neuro-ophthalmology* 2011;35:24-6.
- 485 73. Meecham HM, Humphrey P. Industrial exposure to cobalt causing optic atrophy and nerve deafness: a case report.
486 *J Neurol Neurosurg Psychiatry* 1991;54:374-5.
- 487 74. Jordan CM, Whitman RD, Harbut M. Memory deficits and industrial toxicant exposure: a comparative study of
488 hard metal, solvent and asbestos workers. *Int J Neurosci* 1997;90:113-28.
- 489 75. Christensen JM, Poulsen OM. A 1982-1992 surveillance programme on Danish pottery painters. Biological levels
490 and health effects following exposure to soluble or insoluble cobalt compounds in cobalt blue dyes. *Sci Total Environ*
491 1994;150:95-104.
- 492 76. Prescott E, Netterstrom B, Faber J, Hegedus L, Suadicani P, Christensen JM. Effect of occupational exposure to
493 cobalt blue dyes on the thyroid volume and function of female plate painters. *Scand J Work Environ Health* 1992;18:101-4.
- 494 77. Linna A, Oksa P, Groundstroem K, et al. Exposure to cobalt in the production of cobalt and cobalt compounds and
495 its effect on the heart. *Occup Environ Med* 2004;61:877-85.
- 496 78. Makela KT, Visuri T, Pulkkinen P, et al. Cancer incidence and cause-specific mortality in patients with metal-on-
497 metal hip replacements in Finland. *Acta Orthop* 2014;85:32-8.
- 498 79. Kitahara J, Yamanaka K, Kato K, Lee YW, Klein CB, Costa M. Mutagenicity of cobalt and reactive oxygen
499 producers. *Mutat Res* 1996;370:133-40.
- 500 80. Domingo JL. Cobalt in the environment and its toxicological implications. *Rev Environ Contam Toxicol*
501 1989;108:105-32.
- 502 81. Sunderman FW, Jr. Carcinogenicity of metal alloys in orthopedic prostheses: clinical and experimental studies.
503 *Fundam Appl Toxicol* 1989;13:205-16.
- 504 82. Berry DJ, Harmsen WS, Cabanela ME, Morrey BF. Twenty-five-year survivorship of two thousand consecutive
505 primary Charnley total hip replacements: factors affecting survivorship of acetabular and femoral components. *J Bone Joint*
506 *Surg Am* 2002;84-A:171-7.
- 507 83. Berry DJ. Cemented femoral stems: what matters most. *J Arthroplasty* 2004;19:83-4.
- 508 84. Kavanagh BF, Wallrichs S, Dewitz M, et al. Charnley low-friction arthroplasty of the hip. Twenty-year results with
509 cement. *J Arthroplasty* 1994;9:229-34.
- 510 85. Porter ML, Derbyshire B. RSA study comparing the migration of Charnley Elite and Exeter hip stems. *J*
511 *Arthroplasty* 2003;18:121; author reply -2.
- 512 86. Berry DJ. Long-term follow-up studies of total hip arthroplasty. *Orthopedics* 2005;28:s879-80.
- 513 87. Arthursson AJ, Furnes O, Espehaug B, Havelin LI, Soreide JA. Prosthesis survival after total hip arthroplasty--does
514 surgical approach matter? Analysis of 19,304 Charnley and 6,002 Exeter primary total hip arthroplasties reported to the
515 Norwegian Arthroplasty Register. *Acta Orthop* 2007;78:719-29.
- 516 88. Fowler JL, Gie GA, Lee AJ, Ling RS. Experience with the Exeter total hip replacement since 1970. *Orthop Clin*
517 *North Am* 1988;19:477-89.
- 518 89. Franklin J, Robertsson O, Gestsson J, Lohmander LS, Ingvarsson T. Revision and complication rates in 654 Exeter
519 total hip replacements, with a maximum follow-up of 20 years. *BMC Musculoskelet Disord* 2003;4:6.
- 520 90. Lewthwaite SC, Squires B, Gie GA, Timperley AJ, Ling RS. The Exeter Universal hip in patients 50 years or

- 521 younger at 10-17 years' followup. *Clin Orthop Relat Res* 2008;466:324-31.
- 522 91. Fordham R, Skinner J, Wang X, Nolan J, Exeter Primary Outcome Study G. The economic benefit of hip
523 replacement: a 5-year follow-up of costs and outcomes in the Exeter Primary Outcomes Study. *BMJ open* 2012;2.
- 524 92. O. F, E. D, A. S, A.M. F, G. H, L.I. H. CERAMIC-ON-CERAMIC BEARINGS IN 4926 UNCEMENTED
525 TOTAL HIP ARTHROPLASTIES WITH UP TO 15 YEARS' FOLLOW-UP REPORTED TO THE NORWEGIAN
526 ARTHROPLASTY REGISTER. *Orthopaedic Proceedings* 2018;100-B:53-.
- 527 93. Abdel MP, Roth PV, Harmsen WS, Berry DJ. What is the lifetime risk of revision for patients undergoing total hip
528 arthroplasty? a 40-year observational study of patients treated with the Charnley cemented total hip arthroplasty. *The bone
529 & joint journal* 2016;98-B:1436-40.
- 530 94. Pazzaglia UE, Ghisellini F, Barbieri D, Ceciliani L. Failure of the stem in total hip replacement. A study of
531 aetiology and mechanism of failure in 13 cases. *Arch Orthop Trauma Surg* 1988;107:195-202.
- 532 95. Loudon JR, Charnley J. Subsidence of the femoral prosthesis in total hip replacement in relation to the design of
533 the stem. *J Bone Joint Surg Br* 1980;62-B:450-3.
- 534 96. Kim YH, Kim JS, Yoon SH. Long-term survivorship of the Charnley Elite Plus femoral component in young
535 patients. *J Bone Joint Surg Br* 2007;89:449-54.
- 536 97. Alfaro-Adrian J, Gill HS, Murray DW. Should total hip arthroplasty femoral components be designed to subside?
537 A radiostereometric analysis study of the Charnley Elite and Exeter stems. *J Arthroplasty* 2001;16:598-606.
- 538 98. Jewett BA, Collis DK. Radiographic failure patterns of polished cemented stems. *Clin Orthop Relat Res*
539 2006;453:132-6.
- 540 99. Shon W-Y, Hur C-Y, Moon J-G, Han S-W, Yang J-H, Jang K-M. 2-5 year results of the cemented polished Versys
541 Heritage® femoral stem. *Journal of the Korean Orthopaedic Association* 2008;43:9-16.
- 542 100. Shearwood-Porter N, Browne M, Milton JA, et al. Damage mechanisms at the cement-implant interface of
543 polished cemented femoral stems. *J Biomed Mater Res B Appl Biomater* 2017;105:2027-33.
- 544 101. Hothi HS, Berber R, Panagiotopoulos AC, et al. Clinical significance of corrosion of cemented femoral stems in
545 metal-on-metal hips: a retrieval study. *International orthopaedics* 2016;40:2247-54.
- 546 102. Bryant M, Ward M, Farrar R, et al. Characterisation of the surface topography, tomography and chemistry of
547 fretting corrosion product found on retrieved polished femoral stems. *J Mech Behav Biomed Mater* 2014;32:321-34.
- 548 103. Bryant M, Farrar R, Freeman R, Brummitt K, Nolan J, Neville A. Galvanically enhanced fretting-crevice corrosion
549 of cemented femoral stems. *J Mech Behav Biomed Mater* 2014;40:275-86.
- 550 104. Zhang HY, Blunt L, Jiang XQ, Brown L, Barrans S, Zhao Y. Femoral stem wear in cemented total hip
551 replacement. *Proc Inst Mech Eng H* 2008;222:583-92.
- 552 105. Thomas SR, Shukla D, Latham PD. Corrosion of cemented titanium femoral stems. *J Bone Joint Surg Br*
553 2004;86:974-8.
- 554 106. Willert HG, Broback LG, Buchhorn GH, et al. Crevice corrosion of cemented titanium alloy stems in total hip
555 replacements. *Clin Orthop Relat Res* 1996:51-75.
- 556 107. Kao C, Scalettar R, Bunning RD. Two cases of metallosis from metal-on-polyethylene total hips: an emerging
557 problem. *PM R* 2015;7:447-50.
- 558 108. Meftah M, Haleem AM, Burn MB, Smith KM, Incavo SJ. Early corrosion-related failure of the rejuvenate modular
559 total hip replacement. *J Bone Joint Surg Am* 2014;96:481-7.
- 560 109. Matsen Ko L, Coleman JJ, Stas V, Duwelius PJ. Iliopsoas Irritation as Presentation of Head-Neck Corrosion After
561 Total Hip Arthroplasty: A Case Series. *Orthop Clin North Am* 2015;46:461-8.
- 562 110. McGrory BJ, Payson AM, MacKenzie JA. Elevated Intra-Articular Cobalt and Chromium Levels in Mechanically
563 Assisted Crevice Corrosion in Metal-on-Polyethylene Total Hip Arthroplasty. *J Arthroplasty* 2017;32:1654-8.
- 564 111. McGrory BJ, Jorgensen AH. High Early Major Complication Rate After Revision for Mechanically Assisted
565 Crevice Corrosion in Metal-on-Polyethylene Total Hip Arthroplasty. *J Arthroplasty* 2017;32:3704-10.
- 566 112. Morozov PP, Sana M, McGrory BJ, Farragher SW, Abrahams TG. Comparison of Pre-Revision Magnetic
567 Resonance Imaging and Operative Findings in Mechanically Assisted Crevice Corrosion in Symptomatic Metal-on-
568 Polyethylene Total Hip Arthroplasties. *J Arthroplasty* 2017;32:2535-45.
- 569 113. Hussey DK, McGrory BJ. Ten-Year Cross-Sectional Study of Mechanically Assisted Crevice Corrosion in 1352
570 Consecutive Patients With Metal-on-Polyethylene Total Hip Arthroplasty. *J Arthroplasty* 2017;32:2546-51.
- 571 114. McGrory BJ, McKenney BR. Revision for taper corrosion at the head-neck junction: pearls and pitfalls. *Curr Rev
572 Musculoskelet Med* 2016;9:97-102.
- 573 115. McGrory BJ, MacKenzie J, Babikian G. A High Prevalence of Corrosion at the Head-Neck Taper with
574 Contemporary Zimmer Non-Cemented Femoral Hip Components. *J Arthroplasty* 2015;30:1265-8.
- 575 116. Leibiger T, McGrory BJ. Custom titanium sleeve for surgical treatment of mechanically assisted crevice corrosion

- 576 in the well-fixed, noncontemporary stem in total hip arthroplasty. *Arthroplast Today* 2015;1:107-10.
- 577 117. Collis DK, Mohler CG. Comparison of clinical outcomes in total hip arthroplasty using rough and polished
578 cemented stems with essentially the same geometry. *J Bone Joint Surg Am* 2002;84:586-92.
- 579 118. Howell JR, Jr., Blunt LA, Doyle C, Hooper RM, Lee AJ, Ling RS. In vivo surface wear mechanisms of femoral
580 components of cemented total hip arthroplasties: the influence of wear mechanism on clinical outcome. *J Arthroplasty*
581 2004;19:88-101.
- 582 119. Lieberman IH, Togawa D, Kayanja MM. Vertebroplasty and kyphoplasty: filler materials. *Spine J* 2005;5:305S-
583 16S.
- 584 120. Lohmann CH, Singh G, Willert HG, Buchhorn GH. Metallic debris from metal-on-metal total hip arthroplasty
585 regulates periprosthetic tissues. *World J Orthop* 2014;5:660-6.
- 586 121. Guyer RD, Shellock J, MacLennan B, et al. Early Failure of Metal-on-Metal Artificial Disc Prostheses Associated
587 with Lymphocytic Reaction: Diagnosis and Treatment Experience in Four Cases. *Spine (Phila Pa 1976)* 2011;36:E492-E7.
- 588 122. Huber M, Reinisch G, Zenz P, Zweymuller K, Lintner F. Postmortem study of femoral osteolysis associated with
589 metal-on-metal articulation in total hip replacement: an analysis of nine cases. *J Bone Joint Surg Am* 2010;92:1720-31.
- 590 123. von Schewelov T, Sanzen L. Catastrophic failure due to aggressive metallosis 4 years after hip resurfacing in a
591 woman in her forties--a case report. *Acta Orthop* 2010;81:402-4.
- 592 124. Olliviere B, Darrah C, Barker T, Nolan J, Porteous MJ. Early clinical failure of the Birmingham metal-on-metal hip
593 resurfacing is associated with metallosis and soft-tissue necrosis. *J Bone Joint Surg Br* 2009;91:1025-30.
- 594 125. Beaulé PE, Campbell P, Amstutz HC. Metallosis and metal-on-metal bearings. *J Bone Joint Surg Am* 2000;82:751-
595 2.
- 596 126. Megaterio S GF, Alossa E, Capretto S. Effetti a distanza del rilascio di ioni metallo in usura della testa protesica:
597 presentazione di un caso. *GIOT* 2001;27:173-5.
- 598 127. Steens W, von Foerster G, Katzer A. Severe cobalt poisoning with loss of sight after ceramic-metal pairing in a
599 hip--a case report. *Acta Orthop* 2006;77:830-2.
- 600 128. Oldenburg M, Wegner R, Baur X. Severe cobalt intoxication due to prosthesis wear in repeated total hip
601 arthroplasty. *J Arthroplasty* 2009;24:825 e15-20.
- 602 129. Ikeda T, Takahashi K, Kabata T, Sakagoshi D, Tomita K, Yamada M. Polyneuropathy caused by cobalt-chromium
603 metallosis after total hip replacement. *Muscle Nerve* 2010;42:140-3.
- 604 130. Pelclova D, Sklensky M, Janicek P, Lach K. Severe cobalt intoxication following hip replacement revision:
605 Clinical features and outcome. *Clin Toxicol (Phila)* 2012;50:262-5.
- 606 131. Apel W, Stark D, Stark A, O'Hagan S, Ling J. Cobalt-chromium toxic retinopathy case study. *Doc Ophthalmol*
607 2013;126:69-78.
- 608 132. Dahms K, Sharkova Y, Heitland P, Pankuweit S, Schaefer JR. Cobalt intoxication diagnosed with the help of Dr
609 House. *Lancet* 2014;383:574.
- 610 133. Mao X, Wong AA, Crawford RW. Cobalt toxicity - an emerging clinical problem in patients with metal-on-metal
611 hip prostheses? *Med J Aust* 2011;194:649-51.
- 612 134. Allen LA, Ambardekar AV, Devaraj KM, Maleszewski JJ, Wolfel EE. Clinical problem-solving. Missing elements
613 of the history. *The New England journal of medicine* 2014;370:559-66.
- 614 135. Bisschop R, Boomsma M, Van Raay J, Tiebosch A, Maas M, Gerritsma C. High Prevalence of Pseudotumors in
615 Patients with a Birmingham Hip Resurfacing Prosthesis A Prospective Cohort Study of One Hundred and Twenty-nine
616 Patients. *The Journal of Bone & Joint Surgery* 2013;95:1554-60.
- 617 136. Matthies AK, Skinner JA, Osmani H, Henckel J, Hart AJ. Pseudotumors are common in well-positioned low-
618 wearing metal-on-metal hips. *Clin Orthop Relat Res* 2012;470:1895-906.
- 619 137. Schmalzried TP, Tiberi JV. Metal-metal reactivity: Houston, we have a problem! *Orthopedics* 2010;33:647.
- 620 138. Kwon YM, Thomas P, Summer B, et al. Lymphocyte proliferation responses in patients with pseudotumors
621 following metal-on-metal hip resurfacing arthroplasty. *J Orthop Res* 2009.
- 622 139. Mahendra G, Pandit H, Kliskey K, Murray D, Gill HS, Athanasou N. Necrotic and inflammatory changes in metal-
623 on-metal resurfacing hip arthroplasties. *Acta Orthop* 2009;80:653-9.
- 624 140. Matharu GS, Pandit HG, Murray DW, Judge A. Adverse reactions to metal debris occur with all types of hip
625 replacement not just metal-on-metal hips: a retrospective observational study of 3340 revisions for adverse reactions to
626 metal debris from the National Joint Registry for England, Wales, Northern Ireland and the Isle of Man. *BMC*
627 *Musculoskelet Disord* 2016;17:495.
- 628 141. Sidaginamale RP, Joyce TJ, Bowsher JG, et al. The clinical implications of metal debris release from the taper
629 junctions and bearing surfaces of metal-on-metal hip arthroplasty: joint fluid and blood metal ion concentrations. *The bone*
630 *& joint journal* 2016;98-B:925-33.

- 631 142. Langton DJ, Sidaginamale RP, Joyce TJ, et al. The clinical implications of elevated blood metal ion concentrations
632 in asymptomatic patients with MoM hip resurfacings: a cohort study. *BMJ open* 2013;3.
- 633 143. Langton DJ, Joyce TJ, Jameson SS, et al. Adverse reaction to metal debris following hip resurfacing: the influence
634 of component type, orientation and volumetric wear. *J Bone Joint Surg Br* 2011;93:164-71.
- 635 144. Woelber E, Van Citters DW, Steck T, Glass GA, Tower S. Explant Analysis from a Patient Exhibiting Rapid
636 Acceleration of Parkinson Disease Symptoms and Hypercobaltemia Following Metal-on-Metal Total Hip Arthroplasty: A
637 Case Report. *JBJS Case Connect* 2016;6:e45.
- 638 145. Benelli G, Maritato M, Cerulli Mariani P, Sasso F. Revision of ASR hip arthroplasty: analysis of two hundred and
639 ninety six recalled patients at seven years. *International orthopaedics* 2019;43:97-101.
- 640 146. Green B, Griffiths E, Almond S. Neuropsychiatric symptoms following metal-on-metal implant failure with cobalt
641 and chromium toxicity. *BMC Psychiatry* 2017;17:33.
- 642 147. Gillam MH, Pratt NL, Inacio MC, et al. Heart failure after conventional metal-on-metal hip replacements. *Acta*
643 *Orthop* 2017;88:2-9.
- 644 148. Lehtovirta L, Reito A, Parkkinen J, et al. Analysis of bearing wear, whole blood and synovial fluid metal ion
645 concentrations and histopathological findings in patients with failed ASR hip resurfacings. *BMC Musculoskelet Disord*
646 2017;18:523.
- 647 149. Maurer-Ertl W, Friesenbichler J, Holzer LA, et al. Recall of the ASR XL Head and Hip Resurfacing Systems.
648 *Orthopedics* 2017;40:e340-e7.
- 649 150. Madanat R, Rolfson O, Donahue GS, et al. Medial Calcar Erosion Is Associated With Synovial Thickness in
650 Patients With ASR XL Total Hip Arthroplasty. *J Arthroplasty* 2016;31:2588-92.
- 651 151. Madanat R, Hussey DK, Donahue GS, et al. The Symmetry of Adverse Local Tissue Reactions in Patients with
652 Bilateral Simultaneous and Sequential ASR Hip Replacement. *J Arthroplasty* 2015;30:1794-8.
- 653 152. Wienroth M, McCormack P, Joyce TJ. Precaution, governance and the failure of medical implants: the ASR((TM))
654 hip in the UK. *Life Sci Soc Policy* 2014;10:19.
- 655 153. Fernandez-Valencia J, Gallart X, Bori G, Ramiro SG, Combalia A, Riba J. Assessment of Patients with a DePuy
656 ASR Metal-on-Metal Hip Replacement: Results of Applying the Guidelines of the Spanish Society of Hip Surgery in a
657 Tertiary Referral Hospital. *Adv Orthop* 2014;2014:982523.
- 658 154. Johnson J, Rogers W. Joint issues--conflicts of interest, the ASR hip and suggestions for managing surgical
659 conflicts of interest. *BMC medical ethics* 2014;15:63.
- 660 155. Cip J, von Stempel A, Bach C, Luegmair M, Benesch T, Martin A. Implication of femoral stem on performance of
661 articular surface replacement (ASR) XL total hip arthroplasty. *J Arthroplasty* 2014;29:2127-35.
- 662 156. Shemesh S, Kosashvili Y, Heller S, et al. Hip arthroplasty with the articular surface replacement (ASR) system:
663 survivorship analysis and functional outcomes. *Eur J Orthop Surg Traumatol* 2014;24:925-30.
- 664 157. Jang B, Walsh NA, Bruce WJ. Verification of the Australian Orthopaedic Association National Joint Replacement
665 Registry using a surgeon's database. *J Orthop Surg (Hong Kong)* 2013;21:347-50.
- 666 158. Chang EY, McAnally JL, Van Horne JR, et al. Relationship of plasma metal ions and clinical and imaging findings
667 in patients with ASR XL metal-on-metal total hip replacements. *J Bone Joint Surg Am* 2013;95:2015-20.
- 668 159. Penny JO, Varmarken JE, Ovesen O, Nielsen C, Overgaard S. Metal ion levels and lymphocyte counts: ASR hip
669 resurfacing prosthesis vs. standard THA: 2-year results from a randomized study. *Acta Orthop* 2013;84:130-7.
- 670 160. Jameson SS, Baker PN, Mason J, Porter ML, Deehan DJ, Reed MR. Independent predictors of revision following
671 metal-on-metal hip resurfacing: a retrospective cohort study using National Joint Registry data. *J Bone Joint Surg Br*
672 2012;94:746-54.
- 673 161. Bernthal NM, Celestre PC, Stavrakis AI, Ludington JC, Oakes DA. Disappointing short-term results with the
674 DePuy ASR XL metal-on-metal total hip arthroplasty. *J Arthroplasty* 2012;27:539-44.
- 675 162. Underwood R, Matthies A, Cann P, Skinner JA, Hart AJ. A comparison of explanted Articular Surface
676 Replacement and Birmingham Hip Resurfacing components. *J Bone Joint Surg Br* 2011;93:1169-77.
- 677 163. Matthies A, Underwood R, Cann P, et al. Retrieval analysis of 240 metal-on-metal hip components, comparing
678 modular total hip replacement with hip resurfacing. *J Bone Joint Surg Br* 2011;93:307-14.
- 679 164. Cohen D. OUT OF JOINT. *BMJ: British Medical Journal (Overseas & Retired Doctors Edition)* 2011;342:1116-
680 22.
- 681 165. de Steiger RN, Hang JR, Miller LN, Graves SE, Davidson DC. Five-year results of the ASR XL Acetabular
682 System and the ASR Hip Resurfacing System: an analysis from the Australian Orthopaedic Association National Joint
683 Replacement Registry. *J Bone Joint Surg Am* 2011;93:2287-93.
- 684 166. Langton DJ, Jameson SS, Joyce TJ, et al. Accelerating failure rate of the ASR total hip replacement. *J Bone Joint*
685 *Surg Br* 2011;93:1011-6.

- 686 167. Bijukumar DR, Salunkhe S, Morris D, et al. In Vitro Evidence for Cell-Accelerated Corrosion within Modular
687 Junctions of Total Hip Replacements. *J Orthop Res* 2019.
- 688 168. Siljander MP, Baker EA, Baker KC, Salisbury MR, Thor CC, Verner JJ. Fretting and Corrosion Damage in
689 Retrieved Metal-on-Polyethylene Modular Total Hip Arthroplasty Systems: What Is the Importance of Femoral Head Size?
690 *J Arthroplasty* 2018;33:931-8.
- 691 169. Kwon YM, Tsai TY, Leone WA, Liow MHL. Sensitivity and Specificity of Metal Ion Levels in Predicting
692 "Pseudotumors" due to Taper Corrosion in Patients With Dual Taper Modular Total Hip Arthroplasty. *J Arthroplasty*
693 2017;32:996-1000.
- 694 170. Osman K, Panagiotidou AP, Khan M, Blunn G, Haddad FS. Corrosion at the head-neck interface of current designs
695 of modular femoral components: essential questions and answers relating to corrosion in modular head-neck junctions. *The*
696 *bone & joint journal* 2016;98-B:579-84.
- 697 171. Kolatat K, Perino G, Wilner G, et al. Adverse local tissue reaction (ALTR) associated with corrosion products in
698 metal-on-metal and dual modular neck total hip replacements is associated with upregulation of interferon gamma-mediated
699 chemokine signaling. *J Orthop Res* 2015;33:1487-97.
- 700 172. De Martino I, Assini JB, Elpers ME, Wright TM, Westrich GH. Corrosion and Fretting of a Modular Hip System:
701 A Retrieval Analysis of 60 Rejuvenate Stems. *J Arthroplasty* 2015;30:1470-5.
- 702 173. Gkagkalis G, Mettraux P, Omoumi P, Mischler S, Rudiger HA. Adverse tissue reaction to corrosion at the neck-
703 stem junction after modular primary total hip arthroplasty. *Orthop Traumatol Surg Res* 2015;101:123-6.
- 704 174. Lanting BA, Teeter MG, Vasarhelyi EM, Ivanov TG, Howard JL, Naudie DD. Correlation of corrosion and
705 biomechanics in the retrieval of a single modular neck total hip arthroplasty design: modular neck total hip arthroplasty
706 system. *J Arthroplasty* 2015;30:135-40.
- 707 175. Pivec R, Meneghini RM, Hozack WJ, Westrich GH, Mont MA. Modular Taper Junction Corrosion and Failure:
708 How to Approach a Recalled Total Hip Arthroplasty Implant. *J Arthroplasty* 2014;29:1-6.
- 709 176. Molloy DO, Munir S, Jack CM, Cross MB, Walter WL, Walter WK, Sr. Fretting and corrosion in modular-neck
710 total hip arthroplasty femoral stems. *J Bone Joint Surg Am* 2014;96:488-93.
- 711 177. Hothi HS, Matthies AK, Berber R, Whittaker RK, Skinner JA, Hart AJ. The reliability of a scoring system for
712 corrosion and fretting, and its relationship to material loss of tapered, modular junctions of retrieved hip implants. *J*
713 *Arthroplasty* 2014;29:1313-7.
- 714 178. Cooper HJ, Urban RM, Wixson RL, Meneghini RM, Jacobs JJ. Adverse local tissue reaction arising from
715 corrosion at the femoral neck-body junction in a dual-taper stem with a cobalt-chromium modular neck. *J Bone Joint Surg*
716 *Am* 2013;95:865-72.
- 717 179. Vundelinckx BJ, Verhelst LA, De Schepper J. Taper corrosion in modular hip prostheses: analysis of serum metal
718 ions in 19 patients. *J Arthroplasty* 2013;28:1218-23.
- 719 180. Cooper HJ, Della Valle CJ, Berger RA, et al. Corrosion at the head-neck taper as a cause for adverse local tissue
720 reactions after total hip arthroplasty. *J Bone Joint Surg Am* 2012;94:1655-61.
- 721 181. Hsu AR, Gross CE, Levine BR. Pseudotumor from modular neck corrosion after ceramic-on-polyethylene total hip
722 arthroplasty. *Am J Orthop (Belle Mead NJ)* 2012;41:422-6.
- 723 182. Atwood SA, Patten EW, Bozic KJ, Pruitt LA, Ries MD. Corrosion-induced fracture of a double-modular hip
724 prosthesis: a case report. *J Bone Joint Surg Am* 2010;92:1522-5.
- 725 183. Kretzer JP, Jakubowitz E, Krachler M, Thomsen M, Heisel C. Metal release and corrosion effects of modular neck
726 total hip arthroplasty. *International orthopaedics* 2009;33:1531-6.
- 727 184. Kop AM, Swarts E. Corrosion of a hip stem with a modular neck taper junction: a retrieval study of 16 cases. *J*
728 *Arthroplasty* 2009;24:1019-23.
- 729 185. Kwon YM, Lombardi AV, Jacobs JJ, Fehring TK, Lewis CG, Cabanela ME. Risk stratification algorithm for
730 management of patients with metal-on-metal hip arthroplasty: consensus statement of the American Association of Hip and
731 Knee Surgeons, the American Academy of Orthopaedic Surgeons, and the Hip Society. *J Bone Joint Surg Am* 2014;96:e4.
- 732 186. Jiang H, Liu F, Yang H, Li Y. Effects of cobalt nanoparticles on human T cells in vitro. *Biological trace element*
733 *research* 2012;146:23-9.
- 734 187. Madl AK, Kovochich M, Liang M, Finley BL, Paustenbach DJ, Oberdorster G. Toxicology of wear particles of
735 cobalt-chromium alloy metal-on-metal hip implants Part II: Importance of physicochemical properties and dose in animal
736 and in vitro studies as a basis for risk assessment. *Nanomedicine* 2015;11:1285-98.
- 737 188. Madl AK, Liang M, Kovochich M, Finley BL, Paustenbach DJ, Oberdorster G. Toxicology of wear particles of
738 cobalt-chromium alloy metal-on-metal hip implants Part I: physicochemical properties in patient and simulator studies.
739 *Nanomedicine* 2015;11:1201-15.
- 740 189. Papageorgiou I, Brown C, Schins R, et al. The effect of nano- and micron-sized particles of cobalt-chromium alloy

- 741 on human fibroblasts in vitro. *Biomaterials* 2007;28:2946-58.
- 742 190. Young-Min Kwon M, PhD *, JM, MEng, Paul G. Arauz, PhD., Sensitivity and Specificity of Metal Ion Level in
743 Predicting Adverse
744 Local Tissue Reactions Due to Head-Neck Taper Corrosion in
745 Primary Metal-on-Polyethylene Total Hip Arthroplasty
746 . *Journal of arthroplasty* 2019.
- 747 191. Kwon Y-M, MacAuliffe J, Arauz PG, Peng Y. Sensitivity and specificity of metal ion level in predicting adverse
748 local tissue reactions due to head-neck taper corrosion in primary metal-on-polyethylene total hip arthroplasty. *J*
749 *Arthroplasty* 2018;33:3025-9.
- 750 192. Munemoto M, Grammatopoulos G, Tanaka Y, Gibbons M, Athanasou NA. The pathology of failed McKee-Farrar
751 implants: correlation with modern metal-on-metal-implant failure. *J Mater Sci Mater Med* 2017;28:66.
- 752 193. Willert HG, Buchhorn GH, Fayyazi A, et al. Metal-on-metal bearings and hypersensitivity in patients with artificial
753 hip joints. A clinical and histomorphological study. *J Bone Joint Surg Am* 2005;87:28-36.
- 754 194. Campbell P, Ebrahimzadeh E, Nelson S, Takamura K, De Smet K, Amstutz HC. Histological features of
755 pseudotumor-like tissues from metal-on-metal hips. *Clin Orthop Relat Res* 2010;468:2321-7.
- 756 195. Doorn PF, Mirra JM, Campbell PA, Amstutz HC. Tissue reaction to metal on metal total hip prostheses. *Clin*
757 *Orthop Relat Res* 1996:S187-205.
- 758 196. Somers JF, Dedrye L, Goeminne S. Metal ion levels in ceramic-on-ceramic THR with cobalt-chrome modular
759 necks: analysis of cobalt and chromium serum levels in 23 healthy hip patients. *Hip Int* 2017;27:21-5.
- 760 197. Gill IP, Webb J, Sloan K, Beaver RJ. Corrosion at the neck-stem junction as a cause of metal ion release and
761 pseudotumour formation. *J Bone Joint Surg Br* 2012;94:895-900.
- 762 198. Brodner W, Bitzan P, Meisinger V, Kaider A, Gottsauner-Wolf F, Kotz R. Elevated serum cobalt with metal-on-
763 metal articulating surfaces. *J Bone Joint Surg Br* 1997;79:316-21.
- 764 199. Agency MaHpR. Medical Device Alert: All metal-on-metal (MoM) hip replacements (MDA/2010/033). 2010.
- 765 200. Daniel J, Ziaee H, Pradhan C, Pynsent PB, McMinn DJ. Renal clearance of cobalt in relation to the use of metal-
766 on-metal bearings in hip arthroplasty. *J Bone Joint Surg Am* 2010;92:840-5.
- 767 201. Kwon YM, Glyn-Jones S, Simpson DJ, et al. Analysis of wear of retrieved metal-on-metal hip resurfacing implants
768 revised due to pseudotumours. *J Bone Joint Surg Br* 2010;92:356-61.
- 769 202. Langton DJ, Jameson SS, Joyce TJ, Hallab NJ, Natsu S, Nargol AV. Early failure of metal-on-metal bearings in hip
770 resurfacing and large-diameter total hip replacement: A consequence of excess wear. *J Bone Joint Surg Br* 2010;92:38-46.
- 771 203. Browne JA, Bechtold CD, Berry DJ, Hanssen AD, Lewallen DG. Failed metal-on-metal hip arthroplasties: a
772 spectrum of clinical presentations and operative findings. *Clin Orthop Relat Res* 2010;468:2313-20.
- 773 204. Toms AP, Nolan J, Barker T, Darrach C, Malcolm P. Early failure of a Birmingham resurfacing hip replacement
774 with lymphoreticular spread of metal debris: pre-operative diagnosis with MR. *Br J Radiol* 2009;82:e87-91.
- 775 205. Hart AJ, Sabah S, Henckel J, et al. The painful metal-on-metal hip resurfacing. *J Bone Joint Surg Br* 2009;91:738-
776 44.
- 777 206. Dahlstrand H, Stark A, Anissian L, Hailer NP. Elevated serum concentrations of cobalt, chromium, nickel, and
778 manganese after metal-on-metal alloarthroplasty of the hip: a prospective randomized study. *J Arthroplasty* 2009;24:837-45.
- 779 207. Hart AJ, Skinner JA, Winship P, et al. Circulating levels of cobalt and chromium from metal-on-metal hip
780 replacement are associated with CD8+ T-cell lymphopenia. *J Bone Joint Surg Br* 2009;91:835-42.
- 781 208. Mikhael MM, Hanssen AD, Sierra RJ. Failure of metal-on-metal total hip arthroplasty mimicking hip infection. A
782 report of two cases. *J Bone Joint Surg Am* 2009;91:443-6.
- 783 209. Thomas P, Braathen LR, Dorig M, et al. Increased metal allergy in patients with failed metal-on-metal hip
784 arthroplasty and peri-implant T-lymphocytic inflammation. *Allergy* 2009;64:1157-65.
- 785 210. Clayton RA, Beggs I, Salter DM, Grant MH, Patton JT, Porter DE. Inflammatory pseudotumor associated with
786 femoral nerve palsy following metal-on-metal resurfacing of the hip. A case report. *J Bone Joint Surg Am* 2008;90:1988-
787 93.
- 788 211. Mabillean G, Kwon YM, Pandit H, Murray DW, Sabokbar A. Metal-on-metal hip resurfacing arthroplasty: a
789 review of periprosthetic biological reactions. *Acta Orthop* 2008;79:734-47.
- 790 212. De Smet K, De Haan R, Calistri A, et al. Metal ion measurement as a diagnostic tool to identify problems with
791 metal-on-metal hip resurfacing. *J Bone Joint Surg Am* 2008;90 Suppl 4:202-8.
- 792 213. Jacobs JJ, Hallab NJ. Loosening and osteolysis associated with metal-on-metal bearings: A local effect of metal
793 hypersensitivity? *J Bone Joint Surg Am* 2006;88:1171-2.
- 794 214. Hallab NJ, Anderson S, Caicedo M, Skipor A, Campbell P, Jacobs JJ. Immune responses correlate with serum-
795 metal in metal-on-metal hip arthroplasty. *J Arthroplasty* 2004;19:88-93.

- 796 215. MacDonald SJ. Can a safe level for metal ions in patients with metal-on-metal total hip arthroplasties be
797 determined? *J Arthroplasty* 2004;19:71-7.
- 798 216. Brodner W, Bitzan P, Meisinger V, Kaider A, Gottsauner-Wolf F, Kotz R. Serum cobalt levels after metal-on-
799 metal total hip arthroplasty. *J Bone Joint Surg Am* 2003;85-A:2168-73.
- 800 217. John Cooper H. Corrosion at the Head-Neck Taper as a Cause for Adverse Local Tissue Reactions After Total Hip
801 Arthroplasty. *The Journal of Bone and Joint Surgery (American)* 2012;94:1655.
- 802 218. de Steiger RN, Miller LN, Prosser GH, Graves SE, Davidson DC, Stanford TE. Poor outcome of revised
803 resurfacing hip arthroplasty. *Acta Orthop* 2010;81:72-6.
- 804 219. Gessner BD, Steck T, Woelber E, Tower SS. A Systematic Review of Systemic Cobaltism After Wear or
805 Corrosion of Chrome-Cobalt Hip Implants. *J Patient Saf* 2019;15:97-104.
- 806 220. Editorial: Cobalt in severe renal failure. *Lancet* 1976;2:26-7.
- 807 221. Kriss JP, Carnes WH, Gross RT. Hypothyroidism and thyroid hyperplasia in patients treated with cobalt. *J Am*
808 *Med Assoc* 1955;157:117-21.
- 809 222. Apostoli P, Catalani S, Zaghini A, et al. High doses of cobalt induce optic and auditory neuropathy. *Experimental*
810 *and toxicologic pathology : official journal of the Gesellschaft fur Toxikologische Pathologie* 2013;65:719-27.
- 811 223. Hygienists ACoGI. 2000TLVs and BEIsthreshold limit values
812 for chemical substance and physical agents and biological
813 exposure indices. 2000.
- 814 224. Tvermoes BE, Paustenbach DJ, Kerger BD, Finley BL, Unice KM. Review of cobalt toxicokinetics following oral
815 dosing: Implications for health risk assessments and metal-on-metal hip implant patients. *Crit Rev Toxicol* 2015;45:367-87.
- 816 225. Paustenbach D, Galbraith D, Finley B. Authors' Response to Letters to the Editor Re: Interpreting cobalt blood
817 concentrations in hip implant patients. *Clin Toxicol (Phila)* 2014;52:569-70.
- 818 226. Unice KM, Kerger BD, Paustenbach DJ, Finley BL, Tvermoes BE. Refined biokinetic model for humans exposed
819 to cobalt dietary supplements and other sources of systemic cobalt exposure. *Chem Biol Interact* 2014;216:53-74.
- 820 227. Tvermoes BE, Unice KM, Paustenbach DJ, Finley BL, Otani JM, Galbraith DA. Effects and blood concentrations
821 of cobalt after ingestion of 1 mg/d by human volunteers for 90 d. *Am J Clin Nutr* 2014;99:632-46.
- 822 228. Paustenbach DJ, Galbraith DA, Finley BL. Interpreting cobalt blood concentrations in hip implant patients. *Clin*
823 *Toxicol (Phila)* 2013.
- 824 229. Finley BL, Unice KM, Kerger BD, et al. 31-day study of cobalt(II) chloride ingestion in humans: pharmacokinetics
825 and clinical effects. *J Toxicol Environ Health A* 2013;76:1210-24.
- 826 230. Paustenbach DJ, Tvermoes BE, Unice KM, Finley BL, Kerger BD. A review of the health hazards posed by cobalt.
827 *Crit Rev Toxicol* 2013;43:316-62.
- 828 231. Tvermoes BE, Finley BL, Unice KM, Otani JM, Paustenbach DJ, Galbraith DA. Cobalt whole blood
829 concentrations in healthy adult male volunteers following two-weeks of ingesting a cobalt supplement. *Food and chemical*
830 *toxicology : an international journal published for the British Industrial Biological Research Association* 2013;53:432-9.
- 831 232. Finley BL, Monnot AD, Gaffney SH, Paustenbach DJ. Dose-response relationships for blood cobalt concentrations
832 and health effects: a review of the literature and application of a biokinetic model. *Journal of toxicology and environmental*
833 *health Part B, Critical reviews* 2012;15:493-523.
- 834 233. Unice KM, Monnot AD, Gaffney SH, et al. Inorganic cobalt supplementation: prediction of cobalt levels in whole
835 blood and urine using a biokinetic model. *Food and chemical toxicology : an international journal published for the British*
836 *Industrial Biological Research Association* 2012;50:2456-61.
- 837 234. Finley BL, Monnot AD, Paustenbach DJ, Gaffney SH. Derivation of a chronic oral reference dose for cobalt.
838 *Regulatory toxicology and pharmacology : RTP* 2012;64:491-503.
- 839 235. Bowie EA, Hurley PJ. Cobalt chloride in the treatment of refractory anaemia in patients undergoing long-term
840 haemodialysis. *Aust N Z J Med* 1975;5:306-14.
- 841 236. Duckham JM, Lee HA. Letter: Cobalt cardiomyopathy. *Lancet* 1976;1:1350.
- 842 237. Fung ES, Monnot A, Kovichich M, et al. Characteristics of Cobalt-Related Cardiomyopathy in Metal Hip Implant
843 Patients: An Evaluation of 15 Published Reports. *Cardiovasc Toxicol* 2018;18:206-20.
- 844 238. Rizzetti MC, Liberini P, Zarattini G, et al. Loss of sight and sound. Could it be the hip? *Lancet* 2009;373:1052.
- 845 239. Ng SK, Ebnetter A, Gilhotra JS. Hip-implant related chorio-retinal cobalt toxicity. *Indian journal of ophthalmology*
846 *2013;61:35.*
- 847 240. Gilbert CJ, Cheung A, Butany J, et al. Hip Pain and Heart Failure: The Missing Link. *The Canadian journal of*
848 *cardiology* 2013.
- 849 241. O'Connell E, Mead N, Fesniak H. Idiopathic Cardiomyopathy Following Metal-on-Metal Hip Arthroplasty: The
850 New Face of " Beer Drinker's Cardiomyopathy". *European Journal of Cardiovascular Medicine* 2013;2.

- 851 242. Machado C, Appelbe A, Wood R. Arthroprosthetic Cobaltism and Cardiomyopathy. *Heart, lung & circulation*
852 2012.
- 853 243. Wyles CC, Wright TC, Bois MC, et al. Myocardial Cobalt Levels Are Elevated in the Setting of Total Hip
854 Arthroplasty. *J Bone Joint Surg Am* 2017;99:e118.
- 855 244. Umar M, Jahangir N, Faisal Khan M, Saeed Z, Sultan F, Sultan A. Cobalt cardiomyopathy in hip arthroplasty.
856 *Arthroplast Today* 2019;5:371-5.
- 857 245. Bozic KJ, Browne J, Dangles CJ, et al. Modern metal-on-metal hip implants. *J Am Acad Orthop Surg*
858 2012;20:402-6.
- 859 246. FDA. Metal-on-Metal Hip Implants: FDA Safety
860 Communication. 2013.
- 861 247. Clark M, Prentice J, Hoggard N, Paley M, Hadjivassiliou M, Wilkinson J. Brain structure and function in patients
862 after metal-on-metal hip resurfacing. *American Journal of Neuroradiology* 2014;35:1753-8.
- 863 248. Prentice JR, Clark MJ, Hoggard N, et al. Metal-on-Metal Hip Prostheses and Systemic Health: A Cross-Sectional
864 Association Study 8 Years after Implantation. *PloS one* 2013;8:e66186.
- 865 249. Langton DJ, Sidaginamale RP, Joyce TJ, et al. A comparison study of stem taper material loss at similar and mixed
866 metal head-neck taper junctions. *The bone & joint journal* 2017;99-B:1304-12.
- 867 250. Ashkanfar A, Langton DJ, Joyce TJ. Does a micro-grooved trunnion stem surface finish improve fixation and
868 reduce fretting wear at the taper junction of total hip replacements? A finite element evaluation. *J Biomech* 2017.
- 869 251. Ashkanfar A, Langton DJ, Joyce TJ. A large taper mismatch is one of the key factors behind high wear rates and
870 failure at the taper junction of total hip replacements: A finite element wear analysis. *J Mech Behav Biomed Mater*
871 2017;69:257-66.
- 872 252. Catalani S, Stea S, Beraudi A, et al. Vanadium release in whole blood, serum and urine of patients implanted with
873 a titanium alloy hip prosthesis. *Clin Toxicol (Phila)* 2013;51:550-6.
- 874 253. Zhang HY, Blunt LA, Jiang XQ, Fleming LT, Barrans SM. The influence of bone cement type on production of
875 fretting wear on the femoral stem surface: a preliminary study. *Clin Biomech (Bristol, Avon)* 2012;27:666-72.
- 876 254. Fritz J, Lurie B, Miller TT, Potter HG. MR imaging of hip arthroplasty implants. *Radiographics* 2014;34:E106-32.
- 877 255. Matsen Ko LJ, Pollag KE, Yoo JY, Sharkey PF. Serum Metal Ion Levels Following Total Hip Arthroplasty With
878 Modular Dual Mobility Components. *J Arthroplasty* 2016;31:186-9.
- 879 256. Liu Y, Chen B. In vivo corrosion of CoCrMo alloy and biological responses: a review. *Materials technology*
880 2018;33:127-34.
- 881 257. Willert HG, Buchhorn GH, Fayyazi A, et al. Metal-on-metal bearings and hypersensitivity in patients with artificial
882 hip joints. A clinical and histomorphological study. *J Bone Joint Surg Am* 2005;87:28-36.
- 883 258. Langton DJ, Jameson SS, Joyce TJ, Hallab NJ, Natsu S, Nargol AV. Early failure of metal-on-metal bearings in hip
884 resurfacing and large-diameter total hip replacement: A consequence of excess wear. *J Bone Joint Surg Br* 2010;92:38-46.
- 885 259. Krenn V, Morawietz L, Perino G, et al. Revised histopathological consensus classification of joint implant related
886 pathology. *Pathol Res Pract* 2014;210:779-86.
- 887 260. Langton DJ, Jameson SS, Joyce TJ, Webb J, Nargol AV. The effect of component size and orientation on the
888 concentrations of metal ions after resurfacing arthroplasty of the hip. *J Bone Joint Surg Br* 2008;90:1143-51.
- 889 261. Langton DJ, Spowson AP, Joyce TJ, et al. Blood metal ion concentrations after hip resurfacing arthroplasty: a
890 comparative study of articular surface replacement and Birmingham Hip Resurfacing arthroplasties. *J Bone Joint Surg Br*
891 2009;91:1287-95.
- 892 262. Langton DJ, Spowson AP, Mahadeva D, Bhatnagar S, Holland JP, Nargol AV. Cup anteversion in hip resurfacing:
893 validation of EBRA and the presentation of a simple clinical grading system. *J Arthroplasty* 2010;25:607-13.
- 894 263. Jameson SS, Langton DJ, Nargol AV. Articular surface replacement of the hip: a prospective single-surgeon series.
895 *J Bone Joint Surg Br* 2010;92:28-37.
- 896 264. Langton DJ, Jameson SS, Joyce TJ, et al. Accelerating failure rate of the ASR total hip replacement. *J Bone Joint*
897 *Surg Br* 2011;93:1011-6.
- 898 265. Bolland B, Culliford D, Langton D, Millington J, Arden N, Latham J. High failure rates with a large-diameter
899 hybrid metal-on-metal total hip replacement clinical, radiological and retrieval analysis. *Journal of Bone & Joint Surgery,*
900 *British Volume* 2011;93:608-15.
- 901 266. Bolland BJ, Culliford DJ, Langton DJ, Millington JP, Arden NK, Latham JM. High failure rates with a large-
902 diameter hybrid metal-on-metal total hip replacement: clinical, radiological and retrieval analysis. *J Bone Joint Surg Br*
903 2011;93:608-15.
- 904 267. Langton D, Sidaginamale R, Lord J, Nargol A, Joyce T. Taper junction failure in large-diameter metal-on-metal
905 bearings. *Bone and Joint Research* 2012;1:56-63.

- 906 268. Langton DJ, Sidaginamale RP, Avery P, et al. Retrospective cohort study of the performance of the Pinnacle metal
907 on metal (MoM) total hip replacement: a single-centre investigation in combination with the findings of a national retrieval
908 centre. *BMJ open* 2016;6:e007847.
- 909 269. National Joint Registry for England W, Northern Ireland and the Isle of Man. 14th. annual report 2017. 2017.
- 910 270. Clarke Aea. Total hip replacement and surface replacement of the treatment of pain and disability 2012.
- 911 271. BM Ardaugh SG, RF Redberg. The 510(k) Ancestry of a Metal-on-Metal Hip Implant. *NEJM* 2013;386:97-100.
- 912 272. Emara A, El-Ghawabi S, Madkour O, El-Samra G. Chronic manganese poisoning in the dry battery industry.
913 *Occupational and Environmental Medicine* 1971;28:78-82.
- 914 273. Ishii K. PET approaches for diagnosis of dementia. *American Journal of Neuroradiology* 2014;35:2030-8.
- 915 274. Jiang J, Sun Y, Zhou H, et al. Study of the Influence of Age in 18F-FDG PET Images Using a Data-Driven
916 Approach and Its Evaluation in Alzheimer's Disease. *Contrast media & molecular imaging* 2018;2018.
- 917 275. Mosconi L, Tsui WH, Pupi A, et al. 18F-FDG PET database of longitudinally confirmed healthy elderly
918 individuals improves detection of mild cognitive impairment and Alzheimer's disease. *Journal of Nuclear Medicine*
919 2007;48:1129-34.
- 920 276. Herholz K, Westwood S, Haense C, Dunn G. Evaluation of a calibrated 18F-FDG PET score as a biomarker for
921 progression in Alzheimer disease and mild cognitive impairment. *Journal of Nuclear Medicine* 2011;52:1218-26.
- 922 277. Nasrallah IM, Wolk DA. Multimodality imaging of Alzheimer disease and other neurodegenerative dementias. *J*
923 *Nucl Med* 2014;55:2003-11.
- 924 278. Callender TJ, Morrow L, Subramanian K, Duhon D, Ristovv M. Three-dimensional brain metabolic imaging in
925 patients with toxic encephalopathy. *Environ Res* 1993;60:295-319.
- 926 279. Silverman DH, Mosconi L, Ercoli L, Chen W, Small GW. Positron emission tomography scans obtained for the
927 evaluation of cognitive dysfunction. *Semin Nucl Med* 2008;38:251-61.
- 928 280. Giampreti A, Lonati D, Raghianti B, et al. N-acetyl-cysteine as effective and safe chelating agent in metal-on-
929 metal Hip-Implanted patients: two cases. *Case reports in orthopedics* 2016;2016.
- 930
931

932
933
934
935
936
937
938
939
940
941

Appendix

Cobalt Poisoning by Joint Replacement

Stephen S. Tower, MD

Manuscript submitted to FDA Expert Panel June 2012 addressing the safety of Metal-on-Metal Hip Replacements